

A bad memory

Michael Kühne, Stefan Osswald

Cardiology, University Hospital, Basel

Case report

A 32-year-old male presented to the emergency department at midnight on a Sunday because of acute onset of chest pain. He had carried a piano from one room to another earlier that day. The onset of the chest pain was a few hours later and not related to movement. The patient reported having undergone a heart catheterisation at a different institution about 3

months ago. The report of this procedure was unavailable at the time of presentation, and the patient did not recall the exact results. The past medical history was remarkable for hypertension. His current medical therapy consisted of acetylsalicylic acid 100 mg daily. Physical examination was unremarkable, the blood pressure was 117/78 mm Hg, the heart rate was 68 bpm. His 12-lead ECG is shown in figure 1. Troponin T was within normal limits. Based on the clinical presentation, the

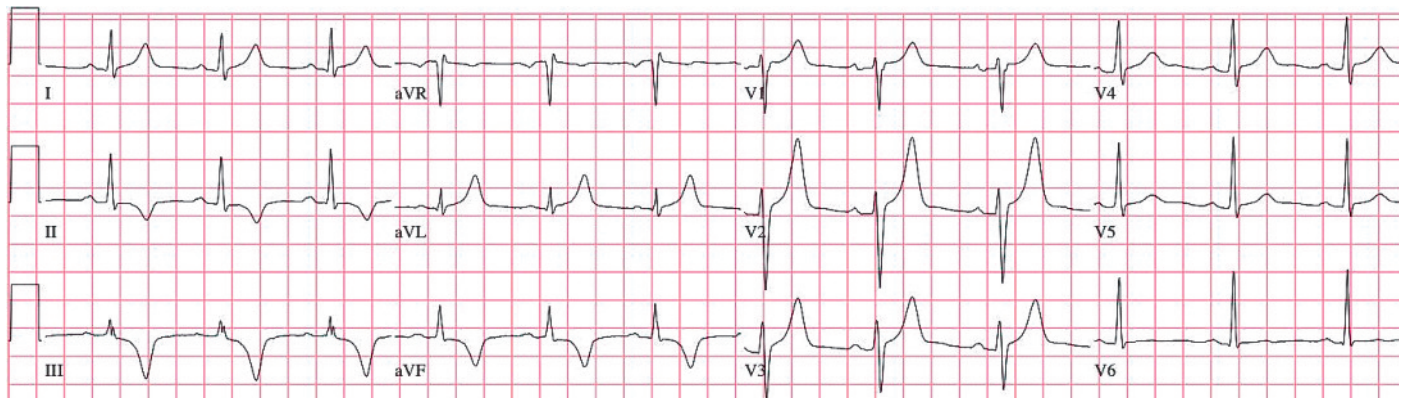
Figure 1

12-lead ECG at the time of presentation with T-wave changes in the inferior leads.

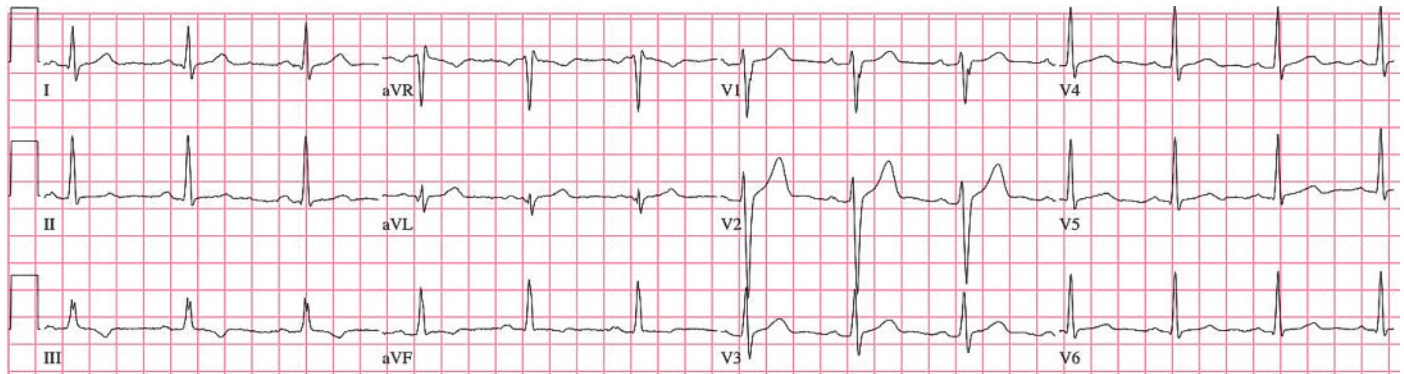

Figure 2

12-lead ECG on the day after radiofrequency catheter ablation of a posteroseptal accessory pathway with deeply inverted T-waves in the inferior leads and tall T-waves in V₂ and V₃ reflecting the axis of the delta wave during preexcitation.



There is no conflict of interest.

Correspondence:
Michael Kühne
Cardiology
University Hospital Basel
Petersgraben 4
CH-4031 Basel
kuehnem@uhbs.ch

ECG and the history of a recent cardiac catheterisation, the patient was hospitalised with a suspected acute coronary syndrome.

The ECG in the morning was unchanged and the troponin remained negative. A prior ECG obtained after the procedure at the outside hospital is shown in figure 2.

Questions

What is the phenomenon shown in the figures?
What procedure did the patient undergo three months ago?

Discussion

The ECG obtained at the emergency department (fig. 1) shows negative T-waves in the inferior leads which are much more pronounced in the ECG obtained after the procedure three months before (fig. 2).

The two ECGs show the phenomenon and the time course of “cardiac memory” in a patient who had undergone successful radiofrequency catheter ablation of a posteroseptal accessory pathway three months before.

The phenomenon of reversible T-wave inversion was initially described by Chatterjee et al. in patients after a period of ventricular pacing and was termed “cardiac memory” by Rosenbaum et al. in 1982 [1, 2]. The phenomenon is based on the fact that altered ventricular activation during ventricular pacing or preexcitation not only changes the vector of depolarisation

(QRS axis), but also the vector of repolarisation (T-wave). After ventricular pacing is turned off or preexcitation is abolished by catheter ablation, the QRS vector is immediately normalised. However, the T-wave vector persists (in the presented case for several months) reflecting the QRS vector during the prior state of altered ventricular activation as if it remembered the period of ventricular pacing or preexcitation [3]. The underlying mechanism of cardiac memory is not entirely understood, but more recent studies have shown that the transient outward potassium current I_{to} appears to play an important role and that modulation of I_{to} function alters the transmural repolarisation gradient [3].

Cardiac memory is a form of electrical remodelling, and in this case mimicked ischaemic ECG changes. Hospitalisation and unnecessary treatment for suspected acute coronary syndrome could most likely have been avoided, if had the treating physicians had access to the patient’s medical records (including prior ECGs and reports on procedures), known about T-wave memory or had the patient remembered the exact circumstances of his heart catheterisation. In this case, the heart remembered what the patient had forgotten.

References

- 1 Chatterjee K, Harris AM, Davies JG, Leatham A. T-wave changes after artificial pacing. *Lancet*. 1969;1:759–60.
- 2 Rosenbaum MB, Blanco HH, Elizari MV, Lazzari JO, Davidenko JM. Electrotonic modulation of the T wave and cardiac memory. *Am J Cardiol*. 1982;50:213–22.
- 3 Rosen MR, Cohen IS. Cardiac memory ... new insights into molecular mechanisms. *J Physiol*. 2006;570:209–18.