

# Unity in diversity: The varied manifestations of WPW syndrome

Andrew De Nazareth<sup>a</sup>, Venkata M. Alla<sup>a</sup>, Claire Hunter<sup>b</sup>

<sup>a</sup> Internal medicine, <sup>b</sup> Cardiology, Creighton University Medical Center, Omaha, NE

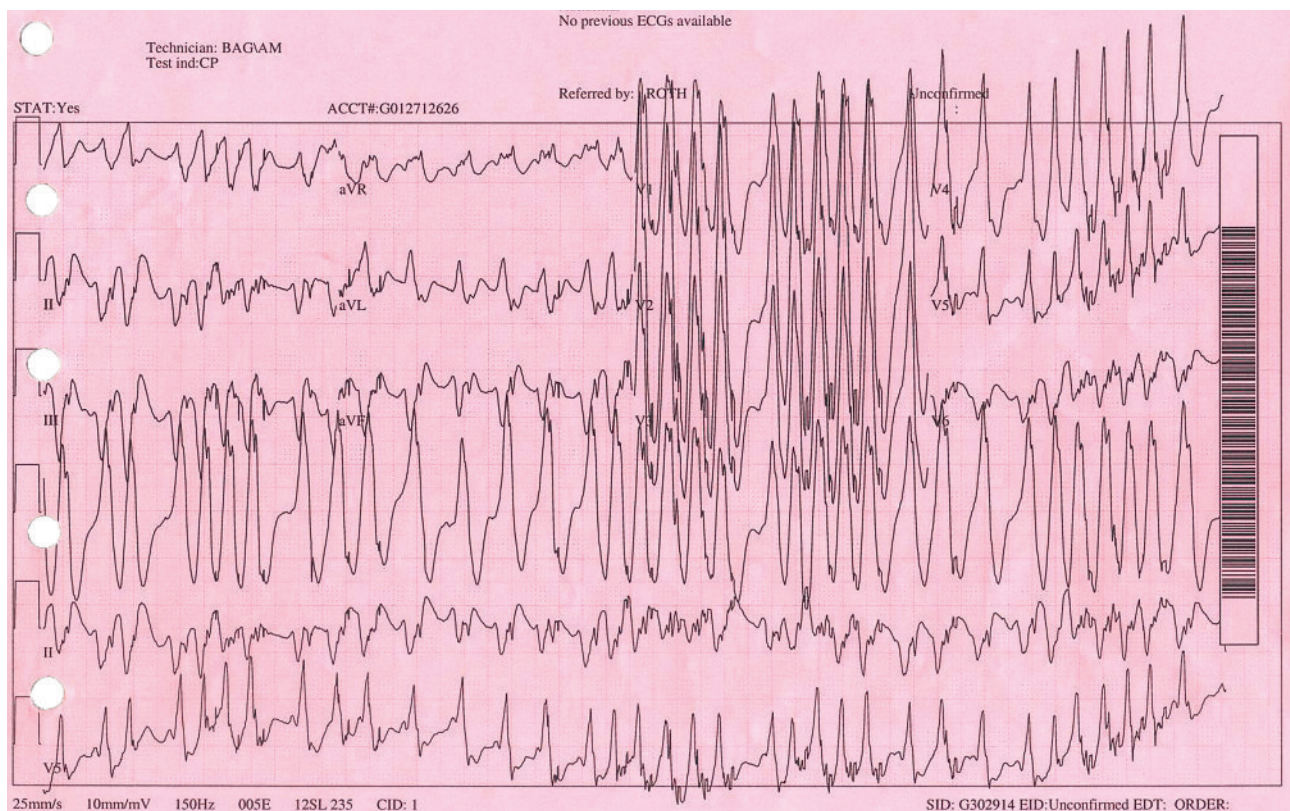A 24-year-old Caucasian male presented to the emergency room with palpitations, lightheadedness and chest tightness for 2 hours. He reported multiple similar episodes lasting for <2 minutes in the preceding 5 years. They were random, occurred without any precipitating cause and he was asymptomatic in the intervening period. His past medical history was unremarkable and he denied use of tobacco, alcohol or illicit drugs. At admission, his pulse was weak, blood pressure was 72/44 mm Hg and EKG (fig. 1) revealed a wide complex tachycardia. Following cardioversion, the

patient developed a narrow QRS tachycardia (fig. 2) requiring repeat cardioversion. Sinus rhythm was restored after a second cardioversion. What is the diagnosis for EKGs one and two? What is likely cause for the patient's symptoms?

## Discussion

The differential for an irregularly wide complex tachycardia (fig. 1) is limited to atrial fibrillation (AF) with aberrant conduction or pre-excitation. In the previously described patient, ventricular rates >200 per minute,

Figure 1



Conflict of interest / disclosures: none.

Correspondence:  
Andrew De Nazareth  
Internal Medicine  
Suite 5850, 601 N 30th Street, Omaha,  
NE-68131, USA

extreme QRS prolongation (>160 ms), bizarre, variable QRS morphology and selective prolongation of early part of QRS vis-à-vis the latter part were useful pointers towards preexcitation. This became obvious once

sinus rhythm was restored (fig. 3). The positive delta wave in V1 to V3 and borderline left axis deviation were consistent with a left sided accessory pathway. The narrow QRS tachycardia that developed following

Figure 2

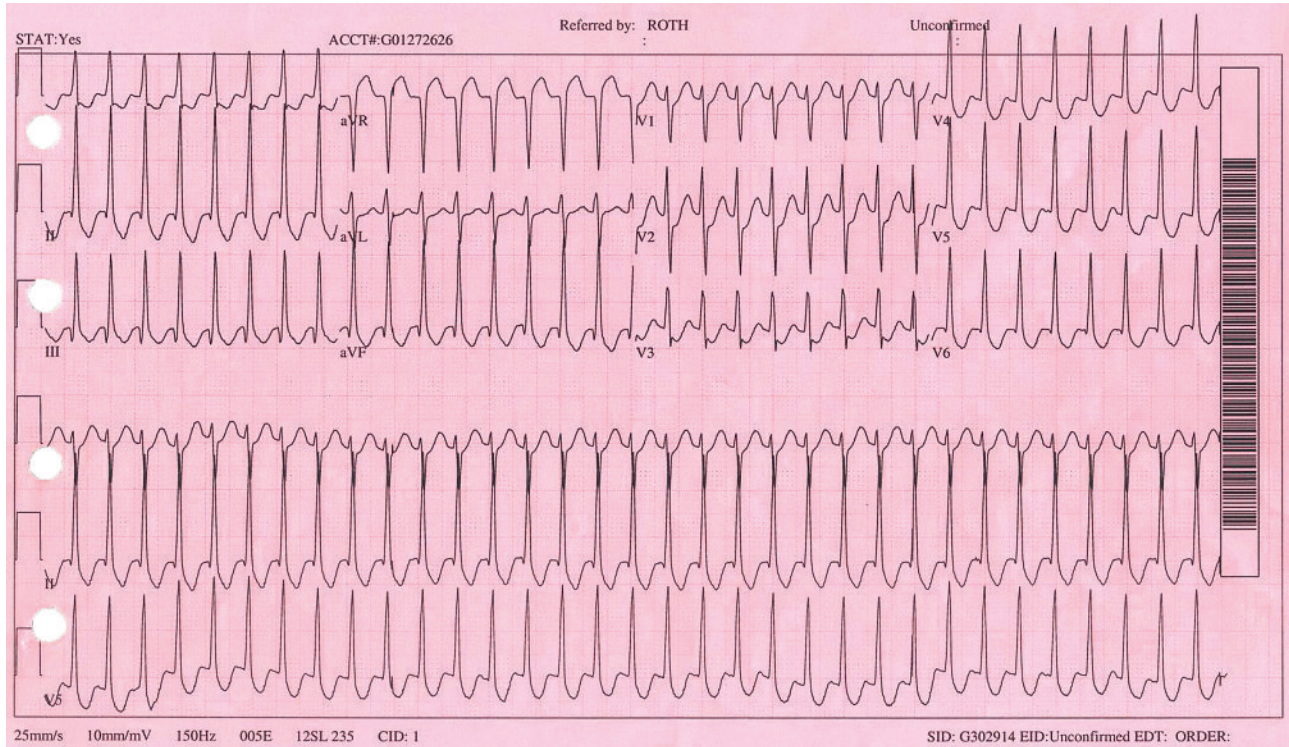
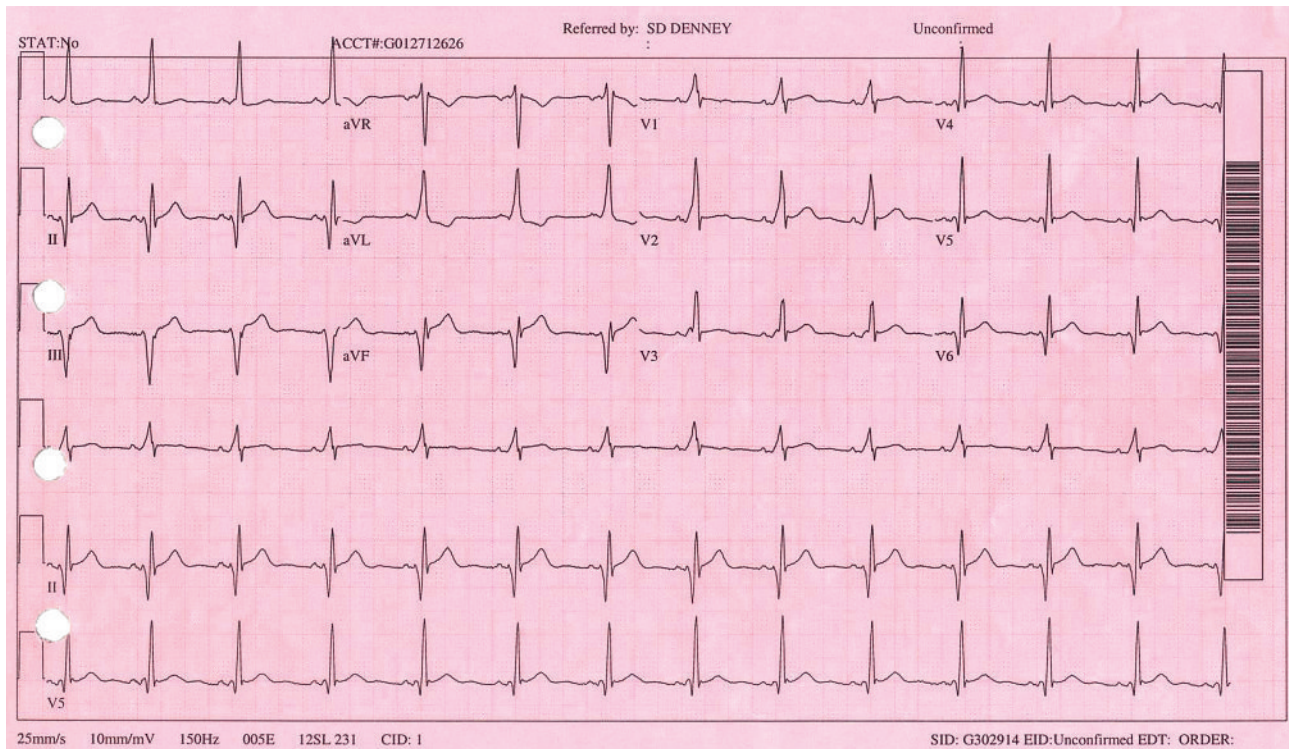


Figure 3



initial cardioversion (fig. 2) is orthodromic atrioventricular reentry tachycardia (AVRT).

The most common arrhythmia in WPW syndrome is AVRT and about 95% of these are orthodromic. The incidence of AF is 15–30% in people with preexcitation as compared to 1% in the general population [1]. The occurrence of AF in WPW syndrome is concerning given the possibility of rapid ventricular rates and degeneration into ventricular fibrillation. The incidence of sudden cardiac death in WPW is 0.1 to 0.6%. Prior SCD, AF, antidromic AVRT, multiple accessory pathways (APs) and short antegrade refractory period of AP are known to increase risk of SCD in WPW syndrome [1, 2]. Proposed mechanisms for AF in WPW syndrome include AP dependant and independent atrial remodeling. However, the exact mechanisms of atrial electrical and structural remodeling have so far not been defined [3].

Management of tachyarrhythmia in WPW syndrome can be difficult. Adenosine, beta-adrenergic blocking agents, calcium channel blocking agents, digoxin and other drugs that slow conduction across the atrioventricular node are contraindicated in patients with AF and antidromic AVRT as they can potentially precipitate ventricular fibrillation. They can however be safely used in patients with orthodromic

AVRT. The drug of choice in patients with antidromic AVRT or AF is procainamide, although amiodarone, propafenone and ibutilide have been successfully used [1]. Cardioversion is the treatment of choice for haemodynamically unstable arrhythmias. Predominant beta blocking property of intravenous amiodarone is potentially concerning. Isolated cases of VF and SCD have been documented with its use.

The currently described patient remained asymptomatic after sinus rhythm was restored and did not develop any further episodes of tachycardia. Serial cardiac markers, complete metabolic panel, blood counts and TSH were normal. Transthoracic echocardiogram was normal with an EF of 55–60%. The patient underwent an electrophysiological study; the AP was localized to the left posterolateral region and was successfully ablated.

## References

- 1 Al-Khatib SM, Pritchett EL. Clinical features of Wolff-Parkinson-White syndrome. *Am Heart J.* 1999;138:403–13.
- 2 Prystowsky EN, Fananapazir L, Packer DL, et al. Wolff-Parkinson-White syndrome and sudden cardiac death. *Cardiology.* 1987;74:67–71.
- 3 Hamada T, Hiraki T, Ikeda H, et al. Mechanisms for atrial fibrillation in patients with Wolff-Parkinson-White syndrome. *J Cardiovasc Electro-physiol.* 2002;13:223–9.