Left ventricular apical ballooning syndrome with extensive myocardial late gadolinium enhancement: Tako-tsubo cardiomyopathy, perhaps not as benign as previously thought?

Vincent Gabus, Juerg Schwitter, Eric Eeckhout, Didier Locca

Service of Cardiology, Department of Internal Medicine, CHUV, Lausanne, Switzerland

Summary

Aim: In patients meeting the criteria for LV apical ballooning syndrome, CMR typically identifies myocardial oedema without Late Gadolinium Enhancement (LGE). However, LGE does not exclude LV apical ballooning syndrome and small necrotic areas can be seen in the acute setting resolving at follow-up.

Results: We describe the case of a 61 year-old woman admitted with a 2 hour history of retrosternal chest pain. ECG demonstrated Q waves and dynamic ST segment elevation. Cardiac enzymes on admission were elevated. Coronary angiography showed unobstructed coronary arteries. Left ventriculography showed apical ballooning. Cardiac Magnetic Resonance (CMR) revealed antero-septal and anterior akinesia. Myocardial oedema was seen in the septal wall. Late gadolinium enhancement (LGE) was seen in the same territory indicating the presence of necrosis. A follow up CMR scan was performed at 3 months showing a complete resolution of the septal oedema. However, on LGE sequences there was evidence of persistent extensive fibrotic scar located in the septal wall. The size of this fibrotic scar was 20% bigger than on the previous scan.

Conclusion: Detection and quantification of a scar is important, as scar tissue on LGE images has been described as a predictor of major adverse cardiac events. Therefore, this case suggests that the spectrum of Tako-tsubo cardiomyopathy may include a more severe variant than previously described. CMR examinations could serve as a useful means to identify severe cases and predict potential complications of this pathology as well as to drive therapeutic decisions.

Key words: Tako-tsubo cardiomyopathy; left ventricular apical ballooning syndrome; cardiac magnetic resonance; late gadolinium enhancement

Funding / potential competing interests:
No financial support and no other potential conflict of interest relevant to this article were reported.

Case report

A 61-year-old woman with known essential hypertension was admitted to the emergency room with a 2 hour history of retrosternal chest pain. She described severe fatigue and emotional stress during the previous week and recalled a similar episode of pain 10 years ago. Current medical therapy at the time of admission included progesterone, enalapril and hydrochlorothiazide. On physical examination she was distressed with a heart rate of 91 beats per minute and blood pressure of 174/100 mm Hg. Clinical examination was otherwise unremarkable. Serial 12 lead ECGs at admission (fig. 1A) demonstrated sinus rhythm with Q waves and dynamic ST segment elevation in V_1–V_3 leads. 24 hours later ECG demonstrated T waves inversion (fig. 1B). An urgent transthoracic echocardiogram was performed showing apical, antero-septal akinesia and antero-lateral hypokinesia with a left ventricular ejection fraction (LVEF) estimated at 50% compatible with apical ballooning. Cardiac enzymes on admission were elevated (Troponin I: 3.55 µg/l [<0.04]; CK: 339 U/l [25–140]) with a peak five hours later (Troponin I: 26.37 µg/l; CK: 825 U/l). Urgent coronary angiography showed unobstructed coronary arteries without any features of spasm (fig. 2A). Left ventriculography (fig. 2B) confirmed the echocardiogram findings showing apical ballooning. Cardiac Magnetic Resonance (CMR) scan (Siemens 1.5T, Erlangen, Germany) was per-

Correspondence:
Vincent Gabus, MD
Department of Internal Medicine
CHUV
Rue du Bugnon
CH-1011 Lausanne
Switzerland
vincent.gabus[at]chuv.ch

Figure 1

A, B Serial 12 lead ECGs demonstrating sinus rhythm with Q waves and dynamic ST segment elevation in V_1–V_3 lead.

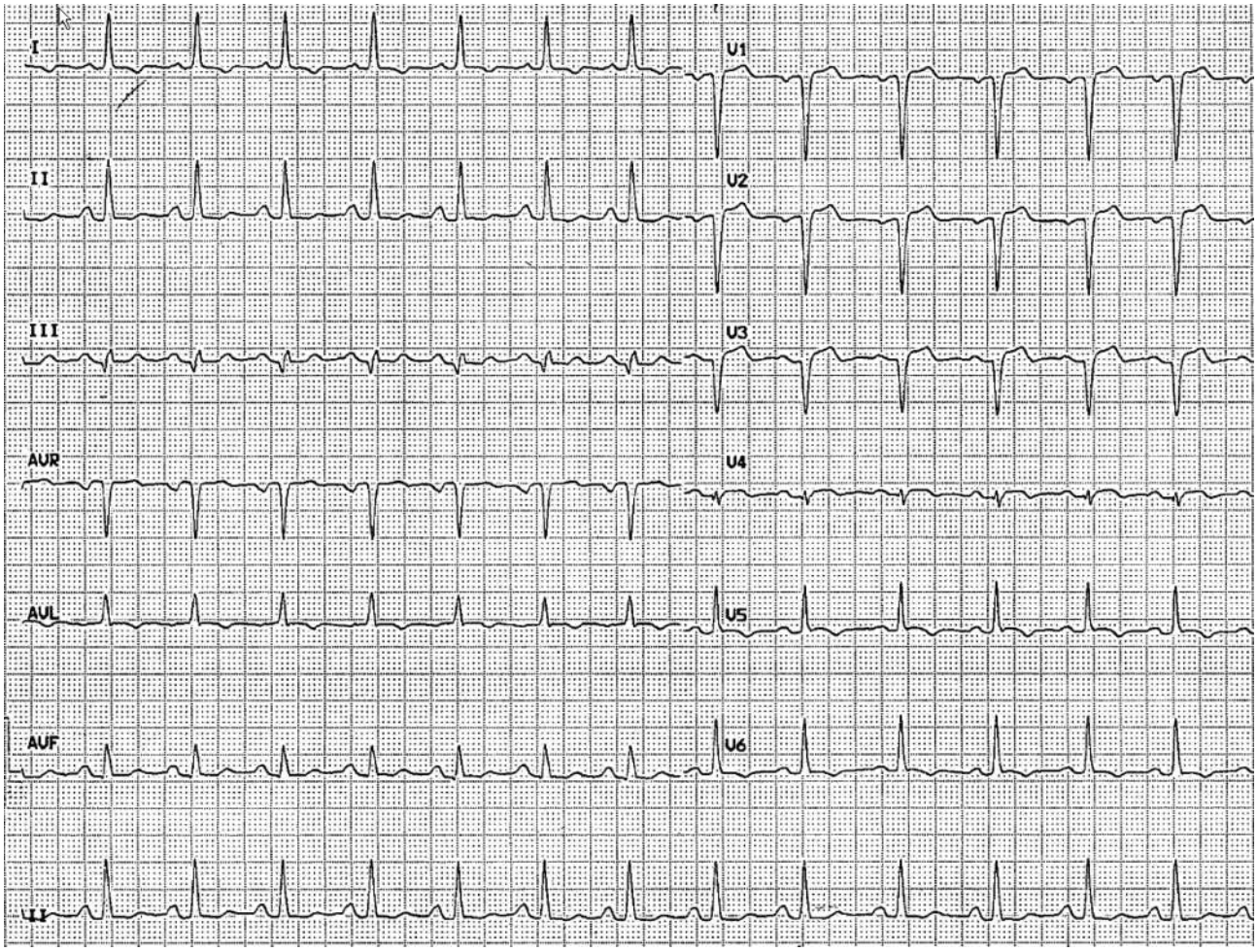

A



B

Figure 2
A Urgent coronary angiography showed unobstructed coronary arteries without any features of spasm.
B Left ventriculography showing apical ballooning.

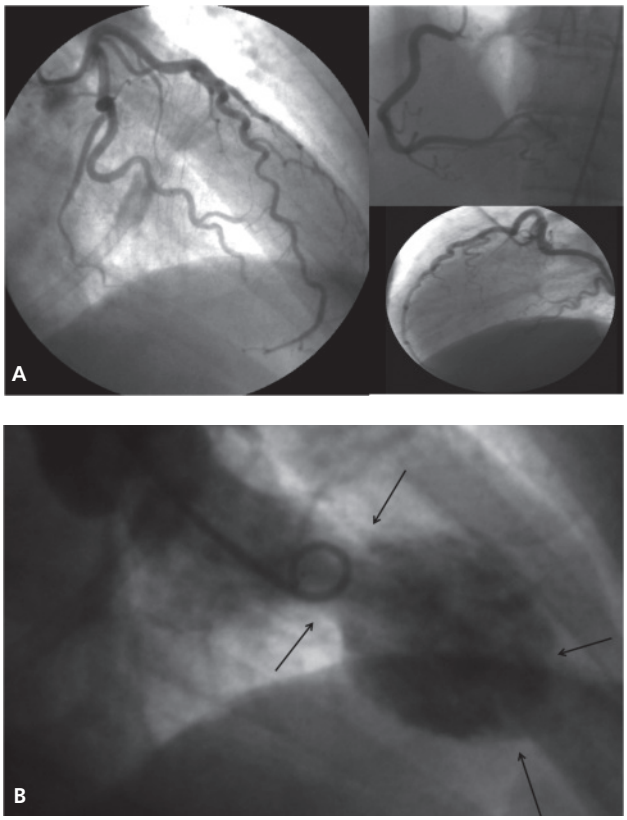

formed 5 days after admission. LVEF calculated from the cine CMR was 50% with antero-septal and anterior akinesia. On the STIR images (T2 weighted sequences, short tau inversion recovery) myocardial oedema was seen in the antero-septal and inferior-septal wall at the mid ventricular level. (fig. 3A, arrows). Late gadolinium enhancement (LGE) was seen in the same territory indicating the presence of necrosis (fig. 4A). Clinical evolution was uneventful and the patient was discharged 9 days post admission. A follow up CMR scan was performed at 3 months showing a preserved LVEF without akinesia and complete resolution of the septal oedema (fig. 3B). However, on LGE sequences there was evidence of extensive persistent, patchy, diffuse subendocardial, mid wall and epicardial fibrotic scar located in the antero-septal and inferior-septal segments (fig. 4B, arrows). The amount of fibrotic tissue was 20% increased in comparison to the previous scan.

Patients meeting the criteria for LV apical ballooning syndrome usually have a modest rise in cardiac enzymes [1]. CMR in these patients typically identifies myocardial oedema without LGE [2]. However, LGE does not exclude LV apical ballooning syndrome and small necrotic areas can be seen in the acute setting resolving at follow-up [3]. Detection and quantification of a scar is important as scar tissue on LGE images has been described as a predictor of major adverse cardiac events [4]. It is unlikely that in our case the territories with LGE in the acute phase represent an incidental

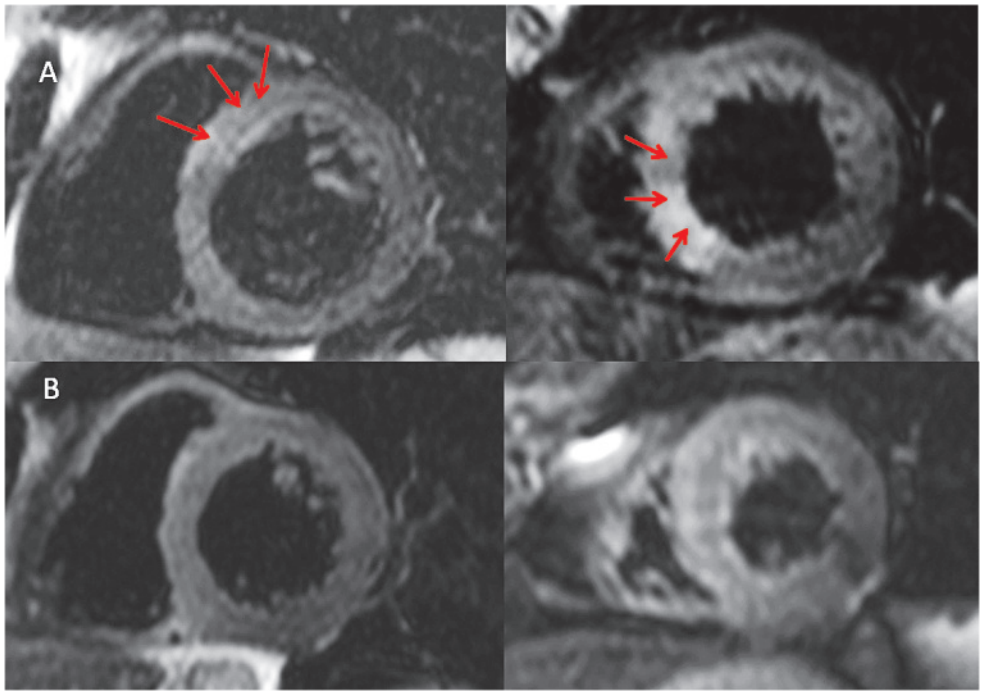

Figure 3
A Cardiac Magnetic Resonance (CMR) scan (Siemens 1.5T, Erlangen, Germany) 5 days after admission. On the STIR images (T2 weighted sequences, short tau inversion recovery) myocardial oedema was seen in the antero-septal and inferior-septal wall at the mid ventricular level (arrows).
B Follow up CMR scan performed at 3 months showing complete resolution of the septal oedema.

Figure 4

A Cardiac Magnetic Resonance (CMR) scan (Siemens 1.5T, Erlangen, Germany) 5 days after admission showing Late gadolinium enhancement (LGE) in the antero-septal and inferior-septal wall indicating the presence of necrosis.

B Follow up CMR scan performed at 3 months. On LGE sequences there is evidence of extensive persistent, patchy, diffuse subendocardial, mid wall and epicardial fibrotic scar located in the antero-septal and inferior-septal segments.

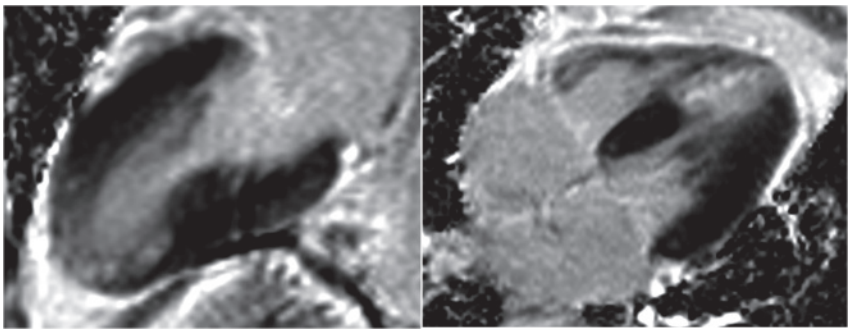

A

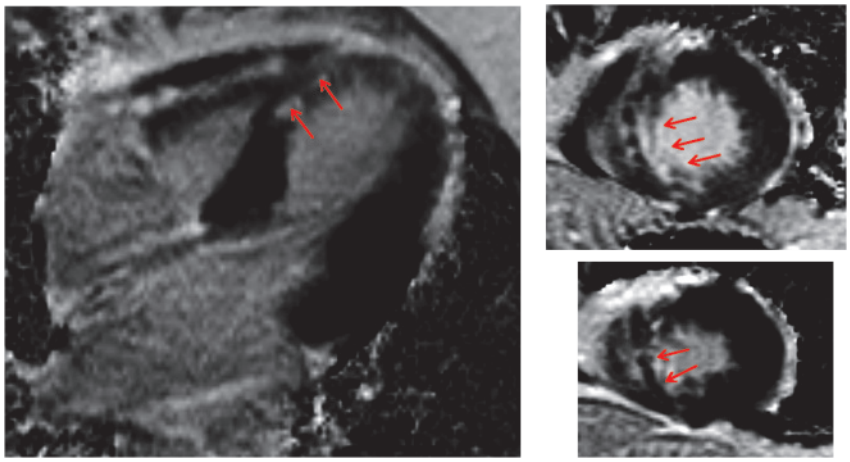

B

finding due to a previous cardiac event, since oedema was detected in the same territories identifying these lesions as acute damage. Therefore, this case suggests that the spectrum of Tako-tsubo cardiomyopathy may include a more severe variant than previously described. CMR examinations of clinical cases presenting with symptoms as described here, could serve as a useful means to identify severe cases and predict potential complications of this pathology as well as to drive therapeutic decisions.

References

1 Prasad A, Lerman A, Rihal CS. Apical ballooning syndrome (Tako-Tsubo or stress cardiomyopathy): a mimic of acute myocardial infarction. Am Heart J. 2008;155:408–17.

2 Eitel I, Behrendt F, Schindler K, Kivelitz D, Gutberlet M, Schuler G, et al. Differential diagnosis of suspected apical ballooning syndrome using contrast-enhanced magnetic resonance imaging. Eur Heart J. 2008;29:2651–9.

3 Rolf A, Nef HM, Möllmann H, Troidl C, Voss S, Conradi G, et al. Immunohistological basis of the late gadolinium enhancement phenomenon in tako-tsubo cardiomyopathy. Eur Heart J. 2009;30:1635–42.

4 Flett A, Westwood M, Davies L, Mathur A, Moon J. The prognostic implications of Cardiovascular Magnetic Resonance. Circ Cardiovasc Imaging. 2009;2:243–50.