

Stroke prevention among atrial fibrillation patients

Left atrial appendage occluder for everyone?

An article from the series «Atrial fibrillation – update 2014»

Ahmed A. Khattab, Bernhard Meier

Cardiology, Cardiovascular Department, Bern University Hospital, Bern, Switzerland

Summary

Left atrial appendage occlusion is based on the observation that most thrombi of atrial fibrillation patients are located in the appendage. The only published randomised trial available so far has demonstrated equal effectiveness of the studied Watchman device compared to warfarin in reducing embolic events and overall mortality. Commercially available devices have all shown safety and effectiveness in clinical registries, even when only antiplatelet agents are given immediately after the procedure and stopped after a few months. Current indications are mainly restricted to patients who are at risk for, or have complications from, oral anticoagulants or object to taking them. Further technical improvements in the devices and the implantation techniques are important to support the propagation of this procedure.

Key words: Atrial fibrillation; left atrial appendage; occlusion stroke

Background and rationale

The left atrial appendage (LAA) is an embryonic remnant of the left atrium, bearing various shapes and morphologies of a long cul-de-sac. Its complex structure with areas of relative slow flow predisposes to stasis, particularly during atrial fibrillation (AF) episodes due to failure of its contractile function, as has been documented on transoesophageal echocardiography (TOE) examination with spontaneous echocardiographic contrast or pulsed-wave Doppler during bouts of AF [1, 2]. It has been shown that in patients with non-valvular AF, 90% of thrombi are present in the LAA [3]. Thrombi detected in the LAA as well as a reduced LAA peak flow velocity were identified as independent predictors of an increased thromboembolic risk [4, 5] and also for recurrent stroke among these patients [6]. Therefore, the rationale of LAA occlusion bases on its exclusion as an embolic source. The remaining other sources of embolism do not warrant oral anticoagulation (OAC) with its inherent risk for major bleeding.

Funding / potential competing interests:

BM has received research grant to the institution and AAK and BM have received speaker/proctor honoraria, all from St. Jude Medical.

History of transcatheter left atrial appendage occlusion

The prototype LAA occlusion device called PLAATO (Percutaneous Left Atrial Appendage Transcatheter Occlusion) was meant to plug the LAA (fig. 1). It was conceived by the electrophysiologist Michael Lesh who assisted when Horst Sievert performed the first such intervention on 30 August 2001 [7]. The PLAATO device had numerous drawbacks and the implantation technique was difficult. Nevertheless clinical results were favourable [8], encouraging development and use of newer, simplified devices.

On 15 June 2002 percutaneous LAA closure without general anaesthesia or echocardiographic guidance in awake patients was introduced by Bernhard Meier using the technically simpler Amplatzer technique [9], utilising the double-disc devices for atrial septal defect (ASD) or patent foramen ovale (PFO) closure. The disc designed for the right side of the interatrial septum in ASD or PFO closure covered the orifice of the LAA reminiscent of the pacifier plate outside a toddler's mouth (pacifier principle). The dedicated Amplatzer Cardiac Plug (ACP) (fig. 1) and LAA delivery sheath were introduced in 2008.

On 12 August 2002 the WATCHMAN device (fig. 1) was clinically introduced by Eugen Hauptmann and Eberhard Grube. It has since undergone several modifications and is approved in many countries worldwide. To date, it is the only device for which data from a randomised trial have been published [10].

In 2010, an LAA patch was introduced by Eleftherios Sideris [11], while other devices are currently in early animal or human trials (e.g. WaveCrest from Coherex, Occlutech, Gore, and Lifetech) (fig. 1). The LAR-IAT technique is a deviceless hybrid intervention combining transcatheter with surgical elements [12, 13].

Correspondence:
Bernhard Meier, MD
Professor and Chairman of Cardiology
Cardiovascular Department
Bern University Hospital
CH-3010 Bern
Switzerland
bernhard.meier[at]insel.ch

Current devices and techniques

Technical description

Two alternative catheter-based concepts for LAA exclusion are closure of the LAA cavity with a mechanical device from inside (endocardial approach)[8–10, 14, 15] or percutaneous suture ligation of the LAA at the level of its orifice from outside using an epicardial approach [13]. Currently, four devices are commercially available for endocardial occlusion, the WATCHMAN device, the ACP, the LAA Patch, and the WaveCrest device (fig. 1). The LARIAT device is used for percutaneous epicardial suture ligation. All these methods have CE-mark approval.

The WATCHMAN device (fig. 1) consists of a nitinol cage with an ultra-thin synthetic membrane covering its left atrial surface. The fixation barbs on the portion opposite the circumference of the LAA minimise the risk of dislodgement. It is attached to a delivery cable and advanced via a 14 French (F) outer diameter single or double curve sheath chosen according to operator judgement. Before or following transseptal puncture in a conventional manner (a low posterior

puncture location is preferred to allow coaxial alignment with the appendage) intravenous heparin is administered maintaining an activated clotting time (ACT) >250 seconds and a pigtail catheter is positioned into the LAA over a soft J-tip 0.035 inch wire. Angiography is performed in several views (typically right anterior oblique caudal and cranial projections) delineating the appendage shape and size. Device oversizing by 10–20% more

than the diameter of the landing zone (measured from the area of the left circumflex coronary artery across the LAA to approximately 1 cm inward from the tip of the ridge separating LAA and left upper pulmonary vein) is mandatory. Subsequently, a stiff J-tip 0.035 inch wire is advanced into the distal LAA and the pigtail catheter and transseptal sheath are exchanged for the access sheath while maintaining wire position. Some operators prefer to place the stiff 0.035 inch wire into the left upper pulmonary vein across the transseptal sheath before exchanging it for the access catheter. Subsequently, a pigtail catheter is again advanced through the access sheath to the LAA to guide the access sheath that has three markers corresponding to device size when it is advanced into the LAA until the distal marker aligns with the ostial plane of the appendage. After de-airing, the device is advanced via a delivery catheter to the distal access sheath, which together with the delivery catheter is slowly withdrawn while maintaining device position until it unfolds. Once deployed, appropriate position and fixation are confirmed via angiography, TOE, and a tug test (demonstrating simultaneous movement of the device and appendage). Optimal position yields minimal protrusion beyond the orifice as well as complete ostial coverage with no or minimal (<5 mm by colour Doppler) residual flow and gentle compression of the device comparing the diameter of the implanted device with its original given diameter. Once adequate positioning confirmed, the device is released. Otherwise it can be retrieved and repositioned or exchanged.

The ACP (fig. 1) consists of a cylindrical nitinol

Figure 1

Clinically used occluders for left atrial appendage closure and their manufacturers.



cage (lobe) crowned by fixation hooks to secure the device in the LAA body. It is connected by a short flexible waist to a slightly larger nitinol plate (disc) destined to cover the LAA ostium. The flexible waist facilitates positioning and adaptation to heterogeneous anatomies. Unlike the WATCHMAN device, the length of the ACP is shorter than its diameter, which enables the ACP to be implanted in relatively short LAAs (implantation can in fact be attempted in virtually all LAAs). Femoral venous access (sheath size 9 to 13 F inner diameter depending on the device size), transseptal puncture, LAA angiography, and TOE imaging (not used in some centres), as well as delivery sheath positioning are performed in a similar manner as described for the WATCHMAN device (fig. 2). The delivery sheath is positioned in the body of the LAA while the lobe is pushed

out. Angiographic control of the position may be done at this point. Then the disc is unfolded by pulling the sheath while fixing the device. With optimal positioning, the lobe should be visibly compressed (tyre-shaped) and adequately separated from the disc to which it is connected by a stretched waist. The disc should be slightly pulled into the LAA (concave appearance) while covering its entire ostium or most of it. After confirmation of an optimal position, the ACP is released, otherwise it may be retracted, repositioned, or exchanged.

An epicardial approach for LAA closure leaving no device behind but only suture material has been proposed. A lasso-like suture, LARIAT snare, is positioned by a percutaneous pericardial puncture technique from the epicardial surface at the base of the LAA and tight-

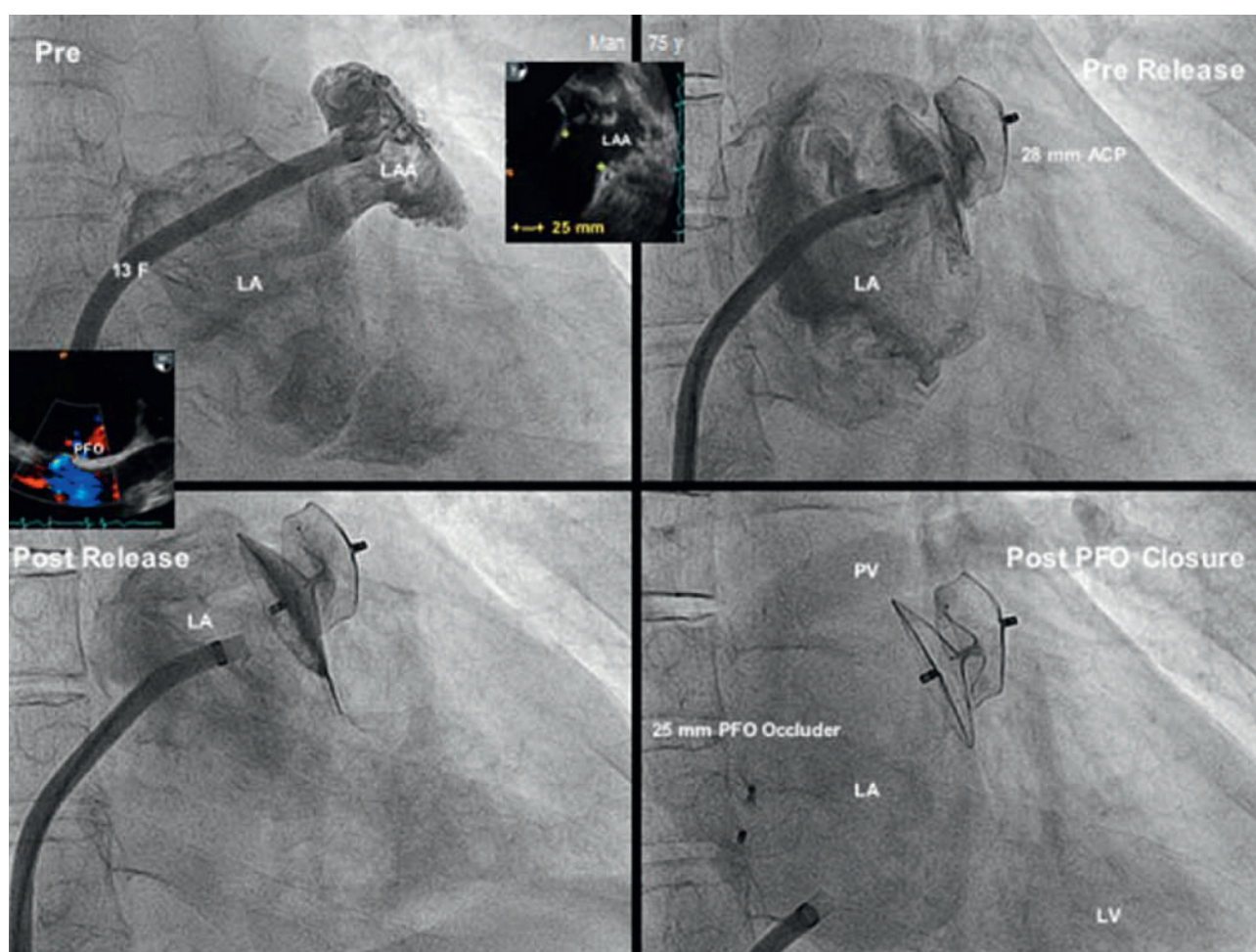


Figure 2

Amplatzer Cardiac Plug (ACP) implantation procedure guided by fluoroscopy.

Top left: Angiographic depiction of left atrial appendage (LAA) in a right anterior oblique projection. The inserts show prior transoesophageal echocardiography (TOE) pictures with a patent foramen ovale (PFO) used for transseptal passage and the LAA in the projection corresponding to angiography.

Top right: Angiographic assessment of deployed Amplatzer Cardiac Plug (ACP) after tug test but before (pre) release.

Bottom left: Angiographic documentation after (post) release.

Bottom right: Situation after closure of the PFO through the same TorqVue sheath.

F = French; LA = left atrium; LV = left ventricle; PV = pulmonary vein; y = years.

ened followed by suture ligation. First, epicardial access is obtained in a similar way as for some electrophysiologic ablations [16], then a soft-tip 14 F access cannula is placed into the pericardial space. Second, a femoral venous access is established and transseptal puncture performed in a conventional manner. A specially designed magnet-tip 0.025 inch endocardial guide wire is advanced into the LAA apex followed by a balloon-mounted catheter via a 8.5 F delivery sheath and its position is confirmed via contrast injection through the balloon catheter lumen. Via the percutaneous epicardial access sheath a second 0.035 inch magnet-tip epicardial wire is advanced toward the LAA and aligned with a magnet located at the distal end of the endocardial wire already located in the LAA apex. Finally, the lasso delivered via the epicardial sheath over the epicardial wire ensnares the LAA ostium and is tightened. Successful occlusion is confirmed by TOE and angiography and the suture is knotted, followed by removal of the endocardial and epicardial gear.

Clinical results

WATCHMAN

Although introduced in 2002, first clinical results were not published until 2007 [17]. The WATCHMAN device is the only LAA occlusion device so far that has been evaluated in a published prospective, controlled, randomised trial. The PROTECT-AF trial examined its efficacy and safety in 707 patients with non-valvular atrial fibrillation (average CHADS₂ score = 2.2 and CHA₂DS₂-VASc score = 3.4) in a non-inferiority design against chronic warfarin therapy [10]. Per protocol all patients were treated with warfarin for 45 days after device implantation to facilitate device endocardialisation. Warfarin was stopped if TOE examination (performed after 45 days, 6 months, and 1 year) showed either complete closure of the LAA or if there was residual peri-device flow of <5 mm in width. Extended follow-up data from 1500 patient-years [18] show that 87% of patients discontinued oral anticoagulation at 45 days and 94% after 2 years of follow-up. Efficacy which was assessed by a primary composite endpoint of stroke, cardiovascular death, and systemic embolism was at 1065 patient-years of follow-up non-significantly different between groups (3.0 per 100 patient-years [95% credible interval 1.9–4.5] in the intervention group and 4.9 per 100 patient-years [2.8–7.1] in the control group [rate ratio 0.62, 95% credible interval 0.35–1.25]). Although there was a higher rate of adverse safety events in the intervention group than in the control group, due mainly to periprocedural complications (pericardial effusion and procedural stroke related to air embolism), the effect of increased operator experience was demonstrated in the more recent Continued Access Protocol (CAP) registry with shorter procedural time, greater procedural success, less proce-

dural complications, and higher warfarin discontinuation rate [19].

Although peri-device flow is frequently observed after WATCHMAN implantation (some degree of peri-device flow was reported in 47% at 45 days and 33% at 12 months), when compared to patients with complete closure there was no difference in thromboembolic events in those with any peri-device flow regardless of whether or not anticoagulation was continued [20]. A recently performed analysis of the net clinical benefit (difference between the annualised rate of serious events in the WATCHMAN group and the rate in the warfarin group, assigning different weights to the events according to severity) in PROTECT-AF and CAP, demonstrated an increased net clinical benefit with higher CHADS₂ scores, especially when the WATCHMAN was used for secondary prevention in patients with previous events [21]. The WATCHMAN device implantation was also associated with an improvement of quality of life compared to warfarin therapy [18].

AMPLATZER device family

The ease of use and long record of low thrombophlebitis of the Amplatzer devices for other indications led to their investigation for percutaneous LAA closure [9] only shortly after the first PLAATO device had been implanted [7]. With the PLAATO device abandoned, the Amplatzer devices have the longest clinical follow-up of currently available LAA occluders. The main drawback of non-dedicated Amplatzer devices was the lack of fixation hooks and unsuitable sheath configurations which resulted in a high embolisation rate of 6% [9]. None of the available Amplatzer devices designed for closure of atrial or ventricular septal defects, patent ductus arteriosus, or vascular shunts proved adequate for LAA closure. This fact spurred the development of the dedicated ACP. The clinical outcome, however, in patients with technically successful Amplatzer LAA closure was already rewarding using the non-dedicated devices with 0.5 events per 100 patient-years compared to the expected 5.5 events without anticoagulation or 1.8 events with anticoagulation according to the CHADS₂ score. Notably, all patients were discharged on antiplatelet therapy only [22].

The ACP device with lobe sizes of 16 to 30 mm diameter and a dedicated double curve sheath with a modified pusher cable has basically supplanted all other Amplatzer devices since its introduction. Initial registry data reflected the technical improvements with a reduction of the embolisation rate to approximately 2% across a wide range of observational studies [13, 14, 23–26]. Pericardial effusion leading to cardiac tamponade requiring interventions occurred in about 2% as did neurological events. These figures are comparable to those obtained with the PLAATO [8] or the WATCHMAN devices [10, 19]. In contrast to the

WATCHMAN device there are no strict anatomical or morphological contraindications (except visible mobile thrombus in the LAA, which is a general contraindication for non-surgical LAA occlusion) for an attempt at LAA closure with an ACP. Technical success in the first 200 registry patients was 97% and a relevant thrombus on the device during follow-up TOE was seen in about 3% [24]. The complete closure rate at sixth month TOE was 99%. This is considerably higher than what can be achieved with the WATCHMAN device. Long-term follow-up data are lacking but design and material of the ACP are so close to that of non-dedicated Amplatzer devices that clinical outcome can be expected to be similar to that mentioned above [22].

Current data support the safety and efficacy of LAA occlusion with both WATCHMAN [27] and ACP device implantation in patients with contraindications to even temporary anticoagulation but also in those amenable to warfarin.

Indications for LAA occlusion

Patients with a contraindication to anticoagulation

Patients with a high thromboembolic risk (CHADS₂ score of >1) but contraindication to oral anticoagulation (e.g., history of a significant bleeding event such as intracranial or major life-threatening bleeding of which the source has not been eliminated) represent the most accepted clinical indication for LAA occlusion, although such patients were not included in the PROTECT-AF study.

Patients with an increased bleeding risk under systemic anticoagulation

Risk assessment using the HAS-BLED score as well as individual evaluation are mandatory. Non-vitamin K antagonist OACs (NOACs) shown to be associated with a lower bleeding risk than vitamin K antagonists may sufficiently reduce this risk. Those in whom vitamin K antagonists and even NOACs are considered to pose an unacceptable bleeding risk but who remain at high stroke risk (CHADS₂ score of >1) should be treated with LAA closure. This also includes patients with an indication for triple anticoagulant therapy, e.g., multiple coronary stents and AF fibrillation. This causes a significant increase in bleeding risk [28], avoidable by LAA occlusion. Patients should be able, however, to receive double antiplatelet therapy for some weeks followed in most cases by life-long single antiplatelet drug therapy. If not even short-term antiplatelet therapy is possible, percutaneous epicardial LAA closure may be an attractive option.

As alternative to oral anticoagulation when oral anticoagulation is possible: LAA occluder for every AF patient?

When patients are eligible for OAC and do not present an increased risk for bleeding, the option of LAA occlusion should be discussed with the patient, although OAC currently remains the standard of care, as recommended in an expert consensus document [29]. The advantages and disadvantages of both treatments should be explained in detail emphasising that randomised data currently are limited to a single study with a single device comparing it in combination with warfarin, an oral vitamin K antagonist against warfarin [10]. It should be clarified that reported favourable results with LAA occlusion compared to oral vitamin K antagonists are based on observational studies and registries. In addition, it should be mentioned that, though the long-term outcome after LAA occlusion (taking into account periprocedural adverse events) may be equivalent to anticoagulation with vitamin K antagonists, serious complications related to the procedure itself (including, but not limited to, the risk of death, stroke, and emergency surgery) may occur. Finally, patients should be alerted to the fact that NOACs are available which, compared to oral vitamin K antagonists, have at least equivalent efficacy, lower rates of intracranial and some agents, also of overall haemorrhage. They do not require surveillance of therapeutic levels. Finally, the decision should be made by a well-informed patient in collaboration with the treating physician.

Conclusion

Although the PROTECT-AF trial has established LAA closure as equally effective as warfarin, current clinical indications are restricted in most centres to patients having complications with, or contraindications to, OAC, or refuse it. This is mainly due to safety issues of current devices. Improvements in devices and techniques for transcatheter LAA occlusion are expected. The results of ongoing randomised trials are awaited to allow wide spread clinical application of this promising technique as a valid alternative for stroke prevention among AF patients. However, this option needs to be discussed with every patient with AF, currently, for most of them, it is only for educational purposes.

References

- 1 Handke M, Harloff A, Hetzel A, Olschewski M, Bode C, Geibel A. Left atrial appendage flow velocity as a quantitative surrogate parameter for thromboembolic risk: determinants and relationship to spontaneous echocontrast and thrombus formation – a transesophageal echocardiographic study in 500 patients with cerebral ischemia. *J Am Soc Echocardiogr.* 2005;18:1366–72.
- 2 Pollick C, Taylor D. Assessment of left atrial appendage function by transesophageal echocardiography. Implications for the development of thrombus. *Circulation.* 1991;84:223–31.
- 3 Blackshear J, Odell J. Appendage obliteration to reduce stroke in cardiac surgical patients with atrial fibrillation. *Ann Thorac Surg.* 1996;61:755–9.

- 4 Zabalgoitia M, Halperin J, Pearce L, Blackshear J, Asinger R, Hart R. Transesophageal echocardiographic correlates of clinical risk of thromboembolism in nonvalvular atrial fibrillation. Stroke Prevention in Atrial Fibrillation III Investigators. *J Am Cardiol.* 1998;31:1622–6.
- 5 Takada T, Yasaka M, Nagatsuka K, Minematsu K, Yamaguchi T. Blood flow in the left atrial appendage and embolic stroke in nonvalvular atrial fibrillation. *Eur Neurol.* 2001;46:148–52.
- 6 Tamura H, Watanabe T, Nishiyama S, Sasaki S, Wanezaki M, Arimoto T, et al. Prognostic value of low left atrial appendage wall velocity in patients with ischemic stroke and atrial fibrillation. *J Am Soc Echocardiogr.* 2012;25:576–83.
- 7 Sievert H, Lesh M, Trepels T, Omran H, Bartorelli A, Della Bella P, et al. Percutaneous left atrial appendage transcatheter occlusion to prevent stroke in high-risk patients with atrial fibrillation: early clinical experience. *Circulation.* 2002;105:1887–9.
- 8 Ostermayer S, Reisman M, Kramer P, Matthews R, Gray W, Block P, et al. Percutaneous left atrial appendage transcatheter occlusion (PLAATO system) to prevent stroke in high-risk patients with non-rheumatic atrial fibrillation: results from the international multi-center feasibility trials. *J Am Cardiol.* 2005;46:9–14.
- 9 Meier B, Palacios I, Windecker S, Rotter M, Cao Q, Keane D, et al. Transcatheter left atrial appendage occlusion with Amplatzer devices to obviate anticoagulation in patients with atrial fibrillation. *Catheter Cardiovasc Interv.* 2003;60:417–22.
- 10 Holmes D, Reddy V, Turi Z, Doshi S, Sievert H, Buchbinder M, et al. Percutaneous closure of the left atrial appendage versus warfarin therapy for prevention of stroke in patients with atrial fibrillation: a randomised non-inferiority trial. *Lancet.* 2009;374:534–42.
- 11 Toumanides S, Sideris E, Agricola T, Mouloupoulos S. Transcatheter patch occlusion of the left atrial appendage using surgical adhesives in high-risk patients with atrial fibrillation. *J Am Cardiol.* 2011;58:2236–40.
- 12 Lee R, Bartus K, Yakubov S. Catheter-based left atrial appendage (LAA) ligation for the prevention of embolic events arising from the LAA: initial experience in a canine model. *Circ Cardiovasc Interv.* 2010;3:224–9.
- 13 Bartus K, Bednarek J, Myc J, Kapelak B, Sadowski J, Lelakowski J, et al. Feasibility of closed-chest ligation of the left atrial appendage in humans. *Heart Rhythm.* 2011;8:188–93.
- 14 Park J, Bethencourt A, Sievert H, Santoro G, Meier B, Walsh K, et al. Left atrial appendage closure with Amplatzer Cardiac Plug in atrial fibrillation: initial European experience. *Catheter Cardiovasc Interv.* 2011;77:700–6.
- 15 Lam Y, Yip G, Yu C, Chan W, Cheng B, Yan B, et al. Left atrial appendage closure with Amplatzer cardiac plug for stroke prevention in atrial fibrillation: initial Asia-Pacific experience. *Catheter Cardiovasc Interv.* 2012;79:794–800.
- 16 Sosa E, Scanavacca M, d'Avila A, Pilleggi F. A new technique to perform epicardial mapping in the electrophysiology laboratory. *J Cardiovasc Electrophysiol.* 1996;7:531–6.
- 17 Sick P, Schuler G, Hauptmann K, Grube E, Yakubov S, Turi Z, Mishkel G, et al. Initial worldwide experience with the Watchman left atrial appendage system for stroke prevention in atrial fibrillation. *J Am Cardiol.* 2007;49:1490–5.
- 18 Holmes D, Reddy V, Turi Z, Doshi S, Sievert H, Buchbinder M, et al. Quality of life assessment in the randomized PROTECT AF trial of patients at risk for stroke with non-valvular atrial fibrillation. *J Am Cardiol.* 2012;59:E240.
- 19 Reddy V, Holmes D, Doshi S, Neuzil P, Kar S. Safety of percutaneous left atrial appendage closure: results from the Watchman Left Atrial Appendage System for Embolic Protection in Patients with AF (PROTECT AF) clinical trial and the Continued Access Registry. *Circulation.* 2011;123:417–24.
- 20 Viles-Gonzalez J, Kar S, Douglas P, Dukkipati S, Feldman T, Horton R, et al. The clinical impact of incomplete left atrial appendage closure with the Watchman Device in patients with atrial fibrillation: a PROTECT AF (Percutaneous Closure of the Left Atrial Appendage Versus Warfarin Therapy for Prevention of Stroke in Patients With Atrial Fibrillation) substudy. *J Am Cardiol.* 2012;59:923–9.
- 21 Gangireddy S, Halperin J, Fuster V, Reddy V. Percutaneous left atrial appendage closure for stroke prevention in patients with atrial fibrillation: an assessment of net clinical benefit. *Eur Heart J.* 2012;33:2700–8.
- 22 Schmid M, Gloekler S, Saguner AM, Wahl A, Fischer U, et al. Transcatheter left atrial appendage closure in patients with atrial fibrillation: comparison between non-dedicated Amplatzer devices. *Cardiovasc Med.* 2013;16(4):123–30.
- 23 Nietlispach F, Gloekler S, Krause R, Shakir S, Schmid M, Khattab AA, et al. Amplatzer left atrial appendage occlusion: single center 10-year experience. *Catheter Cardiovasc Interv.* 2013;82:283–9.
- 24 Park J, Sievert H, Schillinger W, Lickfett L, Lopez-Minguez J, Heyder O, et al. Acute safety results from ACP European multicenter post-market observational study. *EuroIntervention* 2012;8(Suppl):N163.
- 25 López-Minguez J, Eldoayen-Gragera J, González-Fernández R, Fernández-Vegas C, Fuentes-Cañamero M, Millán-Nuñez V, et al. Immediate and one-year results in 35 consecutive patients after closure of left atrial appendage with the Amplatzer cardiac plug. *Rev Esp Cardiol.* 2012: in print.
- 26 Gloekler S, Schmid M, Guerios E, Khattab A, Wenaweser P, Windecker S, et al. Transcatheter left atrial appendage occlusion in atrial fibrillation: a 100 cases single center experience. *EuroIntervention.* 2012; 8:N162.
- 27 Reddy V. Watchman LAA closure device reduces the risk of ischemic stroke in patients with AF entirely without anticoagulation. The ASA-Plavix (ASAP) Registry. Presentation of Transcatheter Therapeutics (TCT), Miami, Florida, USA. November 2012.
- 28 Paikin J, Wright D, Crowther M, Mehta S, Eikelboom J. Triple anti-thrombotic therapy in patients with atrial fibrillation and coronary artery stents. *Circulation.* 2010;121:2067–70.
- 29 Meier B, Blaawu Y, Khattab A, Lewalter T, Sievert H, Tondo C, et al. Left atrial appendage occlusion. Scientific Document by EHRA and EAPCI. *EuroIntervention and EuroPace.* 2014: in print.