

The L wave – a reminder

Nina Eppinger, Micha T. Maeder

Cardiology Division, Kantonsspital St. Gallen, Switzerland

Case report

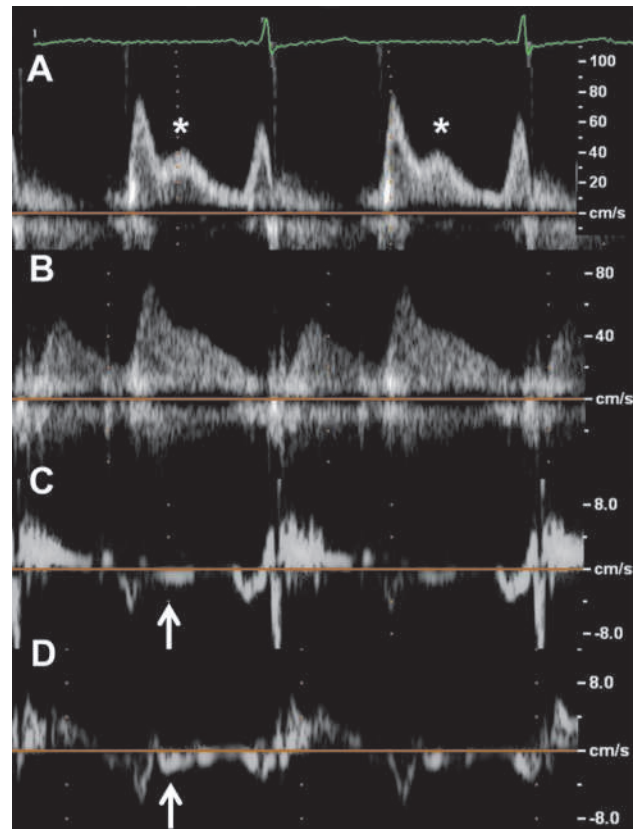
A 78-year-old lady was referred for a pre-operative assessment after a fall with a consecutive fracture of the olecranon. Transthoracic echocardiography showed a normal-sized left ventricle with concentric remodelling and normal ejection fraction, mild mitral regurgitation, and a dilated left atrium (indexed left atrial volume 37 ml/m²). Pulsed wave Doppler of transmitral inflow revealed a ratio of the peak early diastolic (E) to atrial (A) transmitral velocities of 1.3, a deceleration time of 175 ms, and a prominent L wave, i.e., a distinct mid-diastolic transmitral flow from the atrium to the ventricle between the E and A waves (figure, panel A, asterisk). Pulmonary venous flow was predominantly diastolic (figure, panel B). The peak early annular mitral velocities (e') measured at the medial and lateral annulus were reduced (figure, panels C and D), resulting in an elevated E/e' ratio of 13. In the tissue Doppler tracings (figure, panels C and D), small mid-diastolic L' waves were visible (arrows) corresponding to the tissue Doppler correlate of the L wave. Thus, all measurements were consistent with a pseudo-normal mitral filling pattern. The patient's operation and further clinical course were uneventful.

Comment

In subjects with sinus rhythm, the mitral inflow pattern usually consists of two forward flow velocities: the E wave, which represents the rapid filling of the left ventricle after opening of the mitral valve, and the A wave, which represents the late ventricular filling after atrial contraction. According to the classical Wiggers' diagram, there is a period of no flow between the E and the A waves, i.e., diastasis. The L-wave is an additional mid-diastolic flow across the mitral valve, which falls into the period of diastasis of a normal inflow pattern and which results in a triphasic rather than a biphasic pulsed wave Doppler mitral inflow pattern [1]. The L wave has been attributed to continued flow from the pulmonary veins through the left atrium into the left ventricle after early rapid filling [1]. The term "L wave" is based on an earlier nomenclature of the pulmonary venous flow pattern, where the peak systolic and diastolic pulmonary

Funding / potential competing interests:

No financial support and no other potential conflict of interest relevant to this article were reported.



Figure

Transthoracic echocardiography showing key parameters of left ventricular diastolic function.

- Panel A Pulsed wave Doppler of mitral inflow showing the peak velocity of early inflow (E wave), the peak velocity of the mitral inflow after atrial contraction (A wave), and the peak mid-diastolic velocity (L wave; asterisk).
- Panel B: Pulsed wave Doppler of pulmonary venous flow, which is predominantly diastolic.
- Panel C Pulsed wave tissue Doppler of mitral annular motion measured at the medial mitral annulus. The arrow indicates the mid-diastolic mitral annular velocity (L').
- Panel D Pulsed wave tissue Doppler of mitral annular motion measured at the lateral mitral annulus. The arrow indicates the mid-diastolic mitral annular velocity (L').

Correspondence:
Micha T. Maeder, MD
Cardiology Division
Kantonsspital St. Gallen
Rorschacherstrasse 95
CH-9007 St. Gallen
Switzerland
Micha.maeder[at]kssg.ch

venous forward velocities were labelled as J and K waves, which then are followed by an L wave [1]. Thus, an L wave occurs in conditions associated with an abnormal pulmonary venous inflow, i.e., conditions associated with elevated left ventricular filling pressures. The presence of an L wave typically indicates a pseudo-normal mitral inflow pattern [2, 3]. In patients with left ventricular hypertrophy and normal left ventricular ejection fraction, the presence of an L-wave has been found to be associated with the occurrence of heart failure events [3]. An L-wave may also be present in young patients with normal hearts and low heart rate who typically also have a predominantly diastolic pulmonary venous flow [1].

References

- 1 Kerut EK. The mitral L-wave: a relatively common but ignored useful finding. *Echocardiography*. 2008;25:548–50.
- 2 Ha JW, Oh JK, Redfield MM, Ujino K, Seward JB, Tajik AJ. Triphasic mitral inflow velocity with mid-diastolic filling: Clinical implications and associated echocardiographic findings. *J Am Soc Echocardiogr*. 2004;17:428–31.
- 3 Lam CS, Han L, Ha JW, Oh JK, Ling LH. The mitral L wave: a marker of pseudonormal filling and predictor of heart failure in patients with left ventricular hypertrophy. *J Am Soc Echocardiogr*. 2005;18:336–41.