MitraClip™: What should not be done?

Yann Coattrenec[a], Hugo Vanermen[b], Gregory Khatchatourov[c], Jean-Jacques Goy[a]

[a] Division de cardiologie, Hôpital cantonal, Fribourg, Switzerland
[b] Centre de cardiologie, Aalst, Belgium
[c] Clinique Cecil, Lausanne, Switzerland

Introduction

We report the case of a patient with mitral regurgitation in whom MitraClip™ failed after initial surgical mitral repair. A second surgical intervention was needed to cure the patient definitively.

Treatment of mitral regurgitation remains challenging. Recently percutaneous treatment using the MitraClip™ has been proposed as an alternative to surgery with encouraging results [1]. However, MitraClip™ seems to be reserved for nonoperable patients as pointed out by recent data [2].

Case report

A 59-year-old man was referred to our institution for dyspnea. He had a history of mitral valve regurgitation with posterior leaflet valve prolapse. In 2006 he underwent mitral repair without annuloplasty ring implantation. In April 2012 dyspnea, NYHA II–III, recurred. Echocardiography showed grade III to IV mitral regurgitation. He was referred to another hospital, where percutaneous treatment with MitraClip™ implantation was proposed to the patient. Two MitraClips™ were implanted. Shortly after the intervention the patient com-

Figure 1
2D echocardiography showing mitral regurgitation.

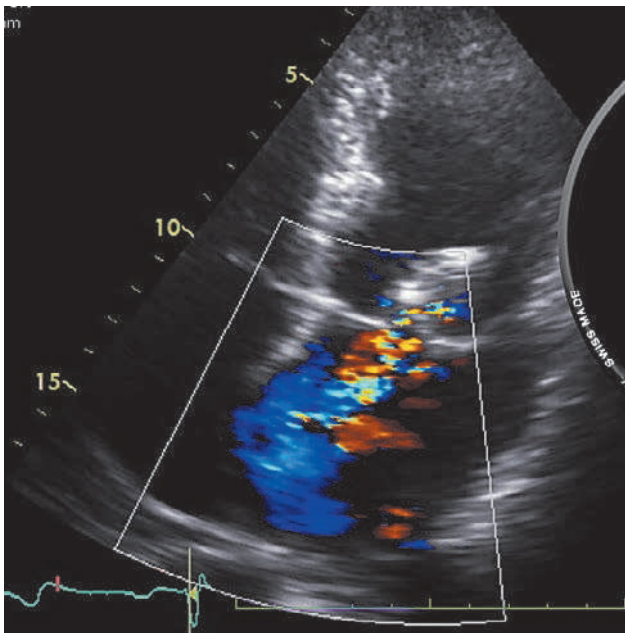

Figure 2
CT scan showing the 2 MitraClips with limitation of the opening of the valve.

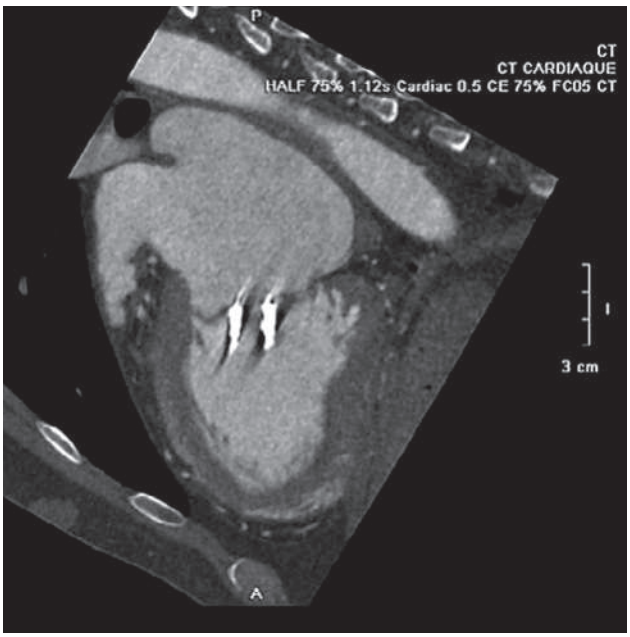

Funding / potential competing interests:
No financial support and no other potential conflict of interest relevant to this article were reported.

Correspondence:
Professor Jean-Jacques Goy, MD
Service de cardiologie, HFR
Rue des Pensionnats 5–7
CH-1700 Fribourg
Switzerland
jjgoy[at]goyman.com

Figure 3
M-mode image with typical patterns of mitral stenoses.

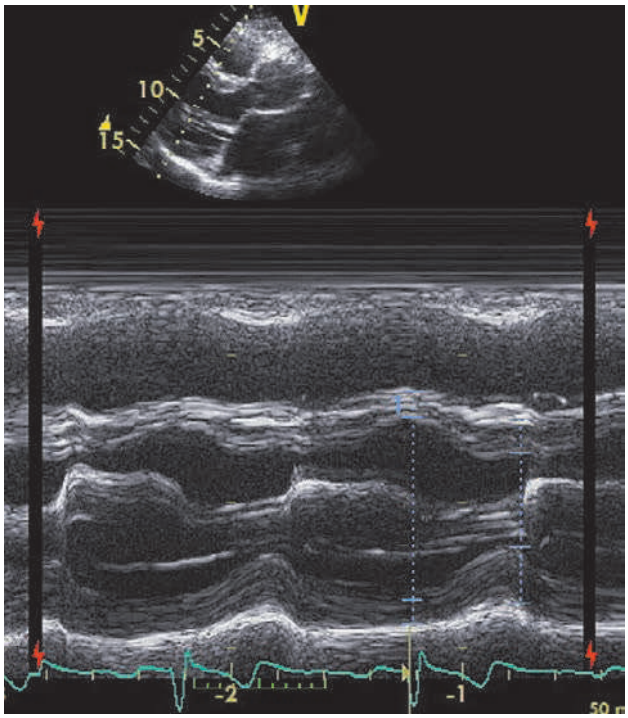

Figure 4
Perioperative stenosis with mitral valve ballooning. The MitraClip is visible on both leaflets.

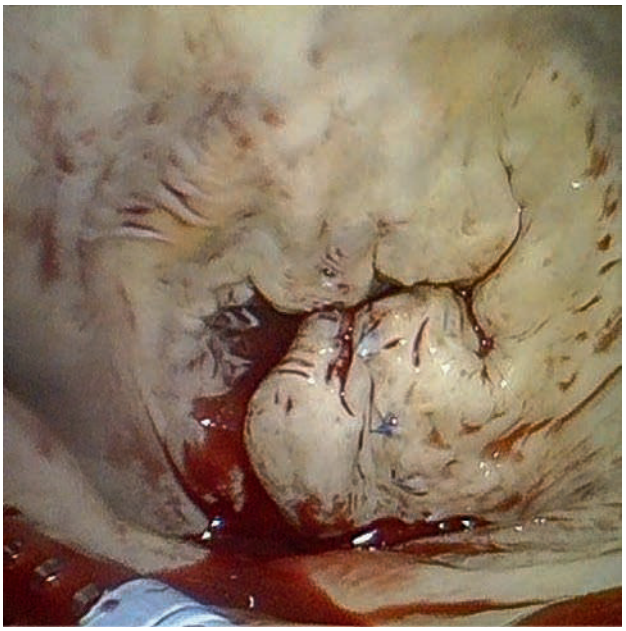

Figure 5
Final result after mitral valve repair and ring implantation.

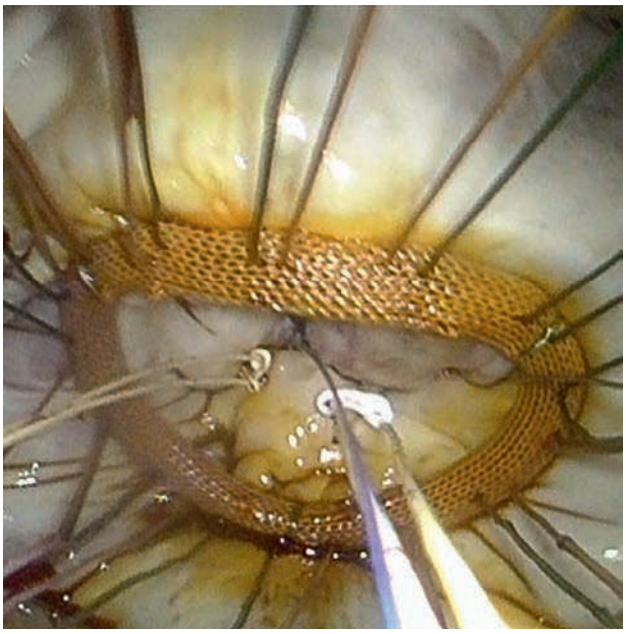

plained about shortness of breath. He was seen at our hospital. Transthoracic echocardiography (fig. 1) and cardiac computed tomography (fig. 2) confirmed the clinical impression of both mitral stenosis and regurgitation with significant gradient and a valve surface of 1.7 cm^2. M-mode echocardiography showed typical patterns of mitral stenosis (fig. 3). Mitral valve repair with annuloplasty could be performed with neocordals, reinforcement of the posterior leaflet and ring implantation (fig. 4 and 5). Six months later, the mitral valve is fully functional and the patient is asymptomatic. This case is remarkable for a few points: firstly, mitral annuloplasty with ring implantation should be performed instead of simple repair. Secondly, equivalence of surgery with MitraClip™ implantation has been proven in some trials. However patients included in these studies were older and sicker than our patient. There are more arguments to suggest that MitraClip™ should be reserved for nonoperable patients or to patients refusing surgery. In our patient, revision surgery was probably a better option than a percutaneous approach. Valve dysfunction requiring a second intervention is almost 10 times more frequent after MitraClip™ implantation than after conventional surgery. Thirdly, even though trials about MitraClip™ are still ongoing, indications should not be lifted to younger patients, until we have clear evidence regarding the comparison of the 2 techniques. Finally, mitral valve repair with annuloplasty and ring implantation is possible after MitraClip™ implantation.

References

1 Mauri L, Foster E, Glower DD, Apruzzese P, Massaro JM, Herrmann HC, et al.; EVEREST II Investigators. Surgery for severe ischemic mitral regurgitation. 4-year results of a randomized controlled trial of percutaneous repair versus surgery for mitral regurgitation. J Am Coll Cardiol. 2013;62:317–28.
2 Glower DD, Kar S, Trento A, Lim DS, Bajwa T, Quesada R, et al. Percutaneous mitral valve repair for mitral regurgitation in high-risk patients: results of the EVEREST II Study. J Am Coll Cardiol. 2014;64:172–81.