

A safe and effective method for pacemaker implantation in children

Axillary vein puncture for device implantation and use of 4F catheter-delivered pacing leads in children

Hania Burgan, Henri Sunthorn, Haran Burri

Cardiology service, University Hospital of Geneva, Switzerland

Summary

Background: Contrast-guided axillary vein puncture has gained popularity for pacemaker and implantable cardioverter defibrillator (ICD) implantation in adults owing to its low risk profile, and could be an alternative to subclavian vein puncture, which is commonly performed in children. The Medtronic 3830 lead is a 4.1F lumenless catheter-delivered lead which may be particularly well-suited for use in the paediatric population because of the reduction in intravascular material and possibility for selective-site lead placement in complex anatomies.

Methods: Data on paediatric patients at our institution aged <15 years who underwent transvenous device implantation using contrast-guided axillary vein puncture were retrieved. Contrast-guided axillary vein puncture was performed in all patients as the primary approach under general anaesthesia.

Results: We retrieved data from 15 patients (7 males), aged 7.7 ± 4.1 yr (range 2–15 yr) at the time of intervention, and weighing 23.0 ± 9.6 kg (range 11.3–38.0 kg). Axillary vein puncture was successful in all patients. We placed 9 right atrial leads, 13 right ventricular pacing leads, 1 right ventricular ICD lead and 1 coronary sinus lead. A 3830 lead was successfully implanted in all 12 patients in whom this lead was intended. There were no procedure-related complications and lead electrical parameters were within normal limits in all patients after a mean follow-up of 13 months.

Conclusion: Contrast-guided axillary vein puncture is a safe and effective method for pacemaker implantation in children. Furthermore, the thin-bodied 3830 lead provides stable pacing parameters while reducing the bulk of intravascular material.

Key words: pacemaker implantation; paediatric; axillary vein puncture; pacemaker lead

Introduction

In children requiring pacemakers and implantable cardioverter defibrillators (ICDs), transvenous leads offer several advantages compared with surgically-placed epicardial leads: a less invasive approach (avoiding repeat pericardiotomy in patients having undergone cardiac surgery), lower capture thresholds (resulting in greater battery longevity) and fewer long-term lead failures [1]. The most common vascular access route for transvenous lead implantation in children is by subclavian vein puncture. The risks inherent to this approach include pneumothorax, haemothorax and subclavian crush, which may be minimised by using contrast-guided axillary vein puncture. We have been performing axillary vein puncture as a first-line approach in adults for over a decade, and have also been applying this technique in the paediatric population, mainly in conjunction with use of a thin (4.1F) SelectSecure model 3830 lead (Medtronic Inc, Minneapolis, MN, USA). The use of this lead in paediatric patients is particularly interesting due to its excellent performance, with a 99% failure-free survival at 5 years according to the manufacturer's product performance report in adults [2], its small diameter (which may reduce venous obstruction) [3], and its flexibility (which may minimise tricuspid valve dysfunction). The lead is lumenless with a central cable design, which means that a stylet cannot be inserted for positioning. A deflectable guiding catheter must be used for lead placement, which also allows contrast injection and selective-site pacing in complex anatomies.

Our aims were (1.) to evaluate contrast-guided axillary vein puncture for lead implantation in children, and (2.) to report our experience with the 3830 lead in our paediatric patient population.

Methods

Data collection

Children who underwent endocardial pacemaker or ICD implantation via axillary vein puncture at our institution were included in the study. Data were retrospectively retrieved from the electronic database of the University Hospital of Geneva from January 2008 to August 2014. The device database (Cardio-report, Medireport, Paris, France) was searched for data on devices implanted in all patients aged 15 years or less, with data exported to an XL file. Relevant patients were retrieved by analysing the lead implantation access (transvenous vs epicardial) and the lead model. For relevant patients, the hospital electronic medical records were analysed for clinical data. The electrical parameters of the leads (bipolar capture thresholds, sensing amplitude and impedance) at implantation and at the last follow-up were extracted. Chest X-rays were retrieved from the hospital electronic medical records to confirm final lead position. The study was approved by the institutional ethics committee.

Implant procedure

Contrast-guided axillary vein puncture

All procedures were performed under general anaesthesia. An incision was made parallel and slightly medial to the deltopectoral groove, with blunt dissection to the pectoralis major muscle and prepectoral (or retropectoral in the case of ICD implantation)

pocket creation. The axillary vein was visualised under fluoroscopy by use of a bolus injection of 10 cc of semidiluted contrast via a venous catheter placed ipsilateral to the side of pacemaker implantation. The vein was punctured during the contrast injection by insertion of an 18G needle (a micropuncture kit was used in the patient with the lowest body weight) while connected to a 10 cc syringe half-filled with saline, under continuous aspiration. The puncture was performed during posteroanterior fluoroscopy (at 8 frames/s). The needle was aligned parallel to and overlying the opacified axillary vein before it was slowly advanced at an approximately 20°–30° angle through the pectoralis major muscle (fig. 1). The lower border of the first rib was sometimes reached with the needle (this marks the limit of the axillary vein and the extrathoracic subclavian vein), but care was taken never to cross the upper border of the first rib because of the risk of pneumothorax. Slight blanching of the opacified vein at the needle-tip heralded puncture of the vein, which was sometimes traversed, with aspiration of blood during careful withdrawal of the needle. As soon as a small quantity of blood was freely aspirated, a 0.035" J-wire was inserted into the axillary vein down to the inferior vena cava. In all but one case with multiple leads, separate punctures were performed under fluoroscopy, using the first guidewire as a landmark (a single puncture for introducing two leads was used, owing to the difficulty of accessing the axillary vein by means of a second stick after the first puncture).

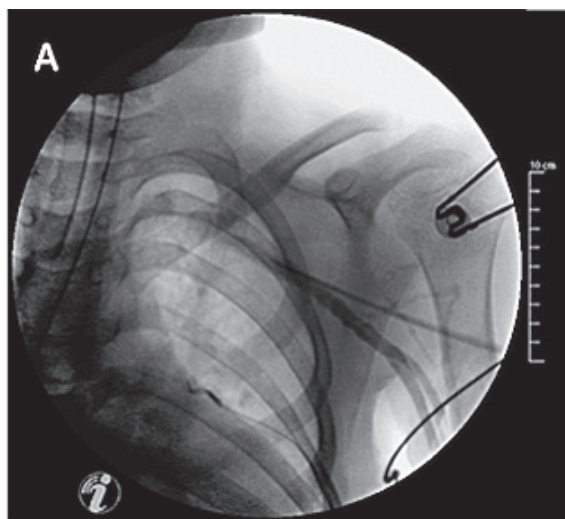


Figure 1: Contrast-guided axillary vein puncture. Note that the needle is aimed coaxially with the vein (downstream to the needle tip).

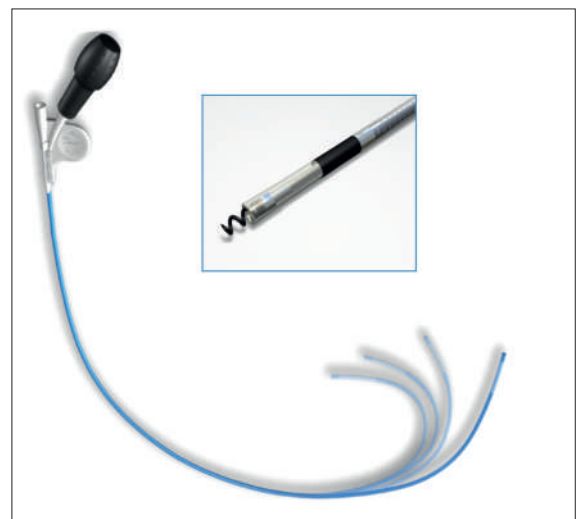

Figure 2: Deflectable 8.5F guiding catheter and SelectSecure 3830 fixed helix lead (reproduced with permission from Medtronic).

Lead placement

In cases with conventional leads, the implantation was performed according to the standard technique. A subset of patients had implantation of the Medtronic 3830 Select Secure lead, which requires a deflectable 8.4F guiding catheter (fig. 2) as there is no lumen to insert a stylet. The guiding catheter was advanced

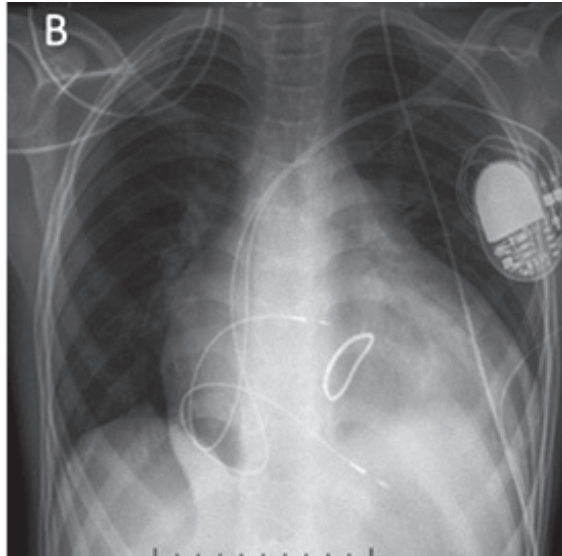


Figure 3: Final position of SelectSecure 3830 leads positioned in the right atrium and right ventricle, with loops to accommodate for future growth. Image from patient 9 (age 14 yr, weight 32.4 kg, height 154 cm)

over a 0.035" J-wire into the right atrium or the right ventricle according to the targeted chamber. The lead is available in two lengths: 59 cm and 69 cm (the extended length is designed to accommodate the guiding catheter), but only the shorter length was used. Atrial leads were implanted in the right atrial appendage. Right ventricular leads were implanted in the apical region (towards the septum). We avoided placing the leads in the mid-septum in order to avoid unintentionally screwing the lead through the septal leaflet or the subvalvular apparatus of the tricuspid valve in these small hearts. The lead has a fixed helix, and was fixated after exposing the lead tip by approximately 1 cm out of the guiding catheter and observing slight buckling of the lead, which indicated contact (visualisation of some current of injury on the electrograms before lead fixation also indicated good contact). The lead body was rotated four to six turns or until slight torque build-up was felt. The guiding catheter was then withdrawn to test for lead stability by pushing the lead, and the electrical parameters were tested after having verified presence of an adequate current of injury. Loops were created in the right atrium to accommodate for future growth and the guiding catheter was then slit (fig. 3). Where multiple leads were implanted, the ventricular lead was implanted first, the guiding catheter slit and the lead fixated with a nonabsorbable suture on the pectora-

Table 1: Patient population data.

Patient	Age (years)	Sex	Weight (kg)	Height (cm)	Indication	Heart disease	Number of leads	Atrial lead	Ventricular lead
1	9	M	34.8	142	AVB III	Congenital lupus	1		3830
2	2	M	11.3	82.5	AVB III	Aortic valve stenosis	2	3830	3830
3	8	F	38.0	138	AVB III	Atrioventricular canal	1		3830
4	15	F	32.0	164	AVB III	Mitral valve and tricuspid valve stenosis	1		3830
5	8	M	20.5	116	AVB III	Mitochondrial disease	2	3830	3830
6	3	F	12.5	90.5	AVB III	Transposition of the great vessels	2	3830	SJM 1084T
7	6	F	13.8	106	AVB III	Tetralogy of Fallot	1		3830
8	3	F	18.2	95	AVB III	Atrioventricular canal	2	3830	3830
9	14	M	32.4	154	AVB III	Mitral valve insufficiency	2	3830	3830
10	13	M	36.8	154	AVB III	Tricuspid valve stenosis	2	3830	SJM 1084T
11	8	F	19.6	121	AVB III	Ventricular and atrial septal defects	1		MDT Starfix 4195 (CS)
12	7	M	19.9	123	AVB III	Idiopathic AVB	2	MDT 5076	MDT 5076
13	4	F	13.0	NA	AVB II	Ventricular septal defect and dextroposition of the great vessels	2	3830	3830
14	5	M	15.0	103	AVB III	Pulmonary artery atresia	2	3830	3830
15	10	F	27.0	141	VT	PCVT	2	MDT 5076	MDT 6935M-55cm

AVB = atrioventricular block; CS = coronary sinus; F = female; M = male; MDT=Medtronic; PCVT = polymorphic catecholergic ventricular tachycardia; SJM = St-Jude Medical; VT = ventricular tachycardia; 3830 = Medtronic SelectSecure 3830 lead

lis major muscle before implanting the second lead. After lead fixation, an absorbable haemostatic suture, which was initially placed at the beginning of the procedure around the 0.035" J-wires, was secured around the venous entrance point of the leads (owing to the mismatch between the diameters of the guiding catheter and of the lead that may cause bleeding).

Results

We retrieved data from 15 patients (7 males), median age 8 yr, interquartile range (IQR) 3–10 yr (range 2–15 yr) at the time of intervention, with a median weight of 19.8 kg, IQR 13.6–33 kg (range 11.3–38.0 kg), and with a median height of 118 cm, IQR 94–145 cm.

Two additional patients implanted via subclavian vein puncture by the cardiovascular surgeons with standard leads were not included in the analysis. The most common indication was symptomatic postoperative third-degree atrioventricular block in patients suffering from structural congenital heart disease. All devices were pacemakers apart from a single ICD (patient 15). Detailed patient information is listed in table 1. Two operators (H.B. and H.S.) placed 10 right atrial pacing leads, 13 right ventricular pacing leads, 1 right ventricular ICD lead and 1 coronary sinus pacing lead. Of these leads, a total of 18 SelectSecure 3830 leads were used for the procedures, including 8 right atrial and 10 right ventricular leads. Duration of fluoroscopy was 12.8 ± 9.8 min (range 5–35 min).

Table 2: Select Secure 3830 electrical parameters at implantation and at follow-up (mean 13.1 ± 22.7 months, range 0–68 months).

	At implantation			At follow-up		
	Sensing (mV)	Capture thresholds (V@0.5 ms)	Impedance (Ohm)	Sensing (mV)	Capture thresholds (V@0.4 ms)	Impedance (Ohm)
Right atrial lead (n = 8)	1.8 ± 1.0	1.4 ± 1.0	559 ± 191	2.8 ± 1.6	0.7 ± 0.4	548 ± 81
Right ventricular lead (n = 9)	8.2 ± 3.4	0.6 ± 0.2	735 ± 133	8.5 ± 5.7	0.9 ± 0.5	502 ± 130

Data are presented as mean \pm standard deviation

Axillary vein puncture was successful in all patients in whom it was attempted, and there was no procedure-related complication (haemo/pneumothorax or lead dislodgement). In the patient in whom a single axillary vein puncture had been performed to introduce two 3830 leads, buckling with retraction of the ventricular lead by about 5 cm at the venous entry site resulted from friction with the atrial guiding catheter during its slitting. The ventricular lead was successfully reinserted into the vein without adverse events. Average loss of haemoglobin points was 0.7 ± 1.1 g/dl (range 0.11–3.4 g/dl). Lead electrical parameters were within normal limits for all leads at implantation and after a mean follow-up of 13 ± 23 months (range 0–68 months) and are shown in table 2.

Discussion

Many centres prefer implanting transvenous pacing leads in children weighing >10 kg rather than placing epicardial leads surgically. Our report indicates that contrast-guided axillary vein puncture for pacemaker and ICD lead implantation in children is safe, with a 100% success rate in our series, which is admittedly of small size. Axillary vein puncture in

children has been previously reported in two series of 18 and 48 patients [4, 5], with a reported success rate of 94%–100%. Our patients were younger at implantation than the patients in these studies, with Silveti et al. [4] reporting a mean age of 12 yr (range 2–18 yr), and Lee et al. [5] reporting a mean age of 9 yr (range 4–15 yr). We also report a lower body weight at implantation compared with these previous studies. Axillary vein puncture is attractive because it is highly successful, safe (with minimal risk of pneumothorax or haemothorax), results in virtually no friction with the clavicle (facilitating lead placement and avoiding subclavian crush) and is easily learnt (it is taught to all device fellows at our institution). Contrast-guided puncture may, however, not be performed in patients who have contrast allergy or in whom it is impossible to insert an ipsilateral venous catheter. We and others have previously described fluoroscopic landmarks that allow axillary vein puncture in adults without contrast injection [6, 7], and another alternative is to use echo guidance [8], although these techniques have not as yet been reported in children. An alternative approach is cephalic venous cutdown, which has also been described in the paediatric population [9]. The advantages of ce-

phalic access is the low risk of subclavian crush and absence of risk of pneumothorax, but may be challenging to perform in small children as a result of the small size of the vein.

The Select Secure 3830 lead is currently being used in adults for transseptal endocardial left ventricular pacing [10, 11] because it can be delivered via a catheter and its high flexibility avoids mitral valve dysfunction. Our report indicates that it may also be used safely in children for conventional pacing. Combining our data with those from three previous paediatric series [12–14], in a total of 98 patients, there have been no serious adverse events reported. In another series of 91 patients with congenital heart disease (and a mean age of 18 ± 8 yr) implanted with the Select Secure 3830 lead [15], there were no serious adverse events reported other than lead dislodgment in one patient. The 8.4F delivery catheter may be considered by some implanting physicians to be too large for this patient population, and alternative delivery methods using smaller guiding catheters have been tested [12, 14]. We, however, did not experience any problems using the deflectable catheter in our patients, and smaller fixed-shape catheters are now available for use with this lead. If multiple leads are implanted, it is advisable to perform separate sticks, as friction with the guiding catheter upon slitting may cause retraction of the first lead, as was the case in our patient in whom a single stick was performed. The SelectSecure 3830 lead does, however, have certain drawbacks. First, it is not (and will probably never be) magnetic resonance imaging (MRI) conditional, as a result of its cable design. This could be a disadvantage in young patients with congenital heart disease, in whom this imaging modality may be very useful. However, most of our patients were referred from developing countries for surgical correction of congenital heart disease, in whom long-term lead performance (in an environment with minimal device follow-up) is more important than MRI conditionality. Second, there are no published data concerning percutaneous lead extraction of the

SelectSecure 3830 lead. The absence of a lumen does not allow use of a locking stylet. However, the cable design of the lead means that it is extremely resistant to traction, as long as the insulation and conducting wires are sutured together if the IS-1 connector pin is cut to allow use of extraction sheaths. A Bulldog lead extender (Cook Medical) may be used to extend the lead if extraction sheaths are used. We have successfully and uneventfully extracted an atrial 3830 lead implanted for 7 years in an 11-year-old child, using only polypropylene sheaths (unpublished data).

Limitations

This is a small retrospective study, with all the caveats inherent to these limitations (i.e., incomplete data, inaccurate success and complication rates, etc.). Follow-up was limited by the fact that most children came from developing countries, and long-term performance of the lead (e.g., after the end of growth) is not available.

Conclusions

On the basis of our experience and previous reports, contrast-guided axillary vein puncture for lead implantation in paediatric patients is a safe and effective approach and has become the method of choice at our institution. The Medtronic SelectSecure 3830 lead is a good option in children, owing to its capability for selective-site pacing, small diameter, high flexibility, and excellent long-term performance. Absence of MRI conditionality and possible issues with lead extraction should nevertheless be borne in mind when opting for this solution.

Disclosures

Dr. Burri: research contracts, speaker honoraria and fellowship support with Medtronic.

References

A full list of references is available in the online version of this article.

Correspondence:
Haran Burri, MD
Cardiology Service
University Hospital
of Geneva, 4, rue Gabrielle-
Perret-Gentil
CH-1211 Geneva 14
Switzerland
haran.burri[at]hcuge.ch

References

- 1 Silveti MS, Drago F, Grutter G, De Santis A, Di Ciommo V, Rava L. Twenty years of paediatric cardiac pacing: 515 pacemakers and 480 leads implanted in 292 patients. *Europace* 2006;8:530–6.
- 2 <http://wwwp.medtronic.com/productperformance/model/3830-selectsecure.html> (accessed on 8.9.2014).
- 3 Figa FH, McCrindle BW, Bigras JL, Hamilton RM, Gow RM. Risk factors for venous obstruction in children with transvenous pacing leads. *Pacing Clin Electrophysiol.* 1997;20:1902–9.
- 4 Silveti MS, Placidi S, Palmieri R, Righi D, Rava L, Drago F. Percutaneous axillary vein approach in pediatric pacing: comparison with subclavian vein approach. *Pacing Clin Electrophysiol.* 2013;36:1550–7.
- 5 Lee JC, Shannon K, Boyle NG, Klitzner TS, Bersohn MM. Evaluation of safety and efficacy of pacemaker and defibrillator implantation by axillary incision in pediatric patients. *Pacing Clin Electrophysiol.* 2004;27:304–7.
- 6 Burri H, Sunthorn H, Dorsaz PA, Shah D. Prospective study of axillary vein puncture with or without contrast venography for pacemaker and defibrillator lead implantation. *Pacing Clin Electrophysiol.* 2005;28:S280–3.
- 7 Antonelli D, Feldman A, Freedberg NA, Turgeman Y. Axillary vein puncture without contrast venography for pacemaker and defibrillator leads implantation. *Pacing Clin Electrophysiol.* 2013;36:1107–10.
- 8 Seto AH, Jolly A, Salcedo J. Ultrasound-guided venous access for pacemakers and defibrillators. *J Cardiovasc Electrophysiol.* 2013;24:370–4.
- 9 Stojanov PL, Savic DV, Zivkovic MB, Calovic ZR. Permanent endovenous pediatric pacing: absence of lead failure—20 years follow-up study. *Pacing Clin Electrophysiol.* 2008;31:1100–7.
- 10 Morgan JM, Scott PA, Turner NG, Yue AM, Roberts PR. Targeted left ventricular endocardial pacing using a steerable introducing guide catheter and active fixation pacing lead. *Europace* 2009;11:502–6.
- 11 Lau EW. A streamlined technique of trans-septal endocardial left ventricular lead placement. *J Interv Card Electrophysiol.* 2009;26:73–81.
- 12 Lapage MJ, Rhee EK. Alternative delivery of a 4Fr lumenless pacing lead in children. *Pacing Clin Electrophysiol.* 2008;31:543–7.
- 13 Chakrabarti S, Morgan GJ, Kenny D, Walsh KP, Oslizlok P, Martin RP, et al. Initial experience of pacing with a lumenless lead system in patients with congenital heart disease. *Pacing Clin Electrophysiol.* 2009;32:1428–33.
- 14 Kenny D, Walsh KP. Noncatheter-based delivery of a single-chamber lumenless pacing lead in small children. *Pacing Clin Electrophysiol.* 2007;30:834–8.
- 15 Khan A, Zelin K, Karpawich PP. Performance of the lumenless 4.1-Fr diameter pacing lead implanted at alternative pacing sites in congenital heart: a chronic 5-year comparison. *Pacing Clin Electrophysiol.* 2010;33:1467–74.