

A travelling Port-a-Cath in a 2-year-old

A patent foramen ovale may be dangerous ... even in childhood

Jean-Pierre Pfammatter, Bernhard Meier

Centre for Congenital Heart Disease, Swiss Cardiovascular Centre, University Hospital of Bern, Inselspital Bern, Switzerland

A 2-year-old boy was diagnosed with acute lymphatic leukaemia. For treatment a Port-a-Cath system was implanted surgically in standard fashion via the right subclavian vein (fig. 1).

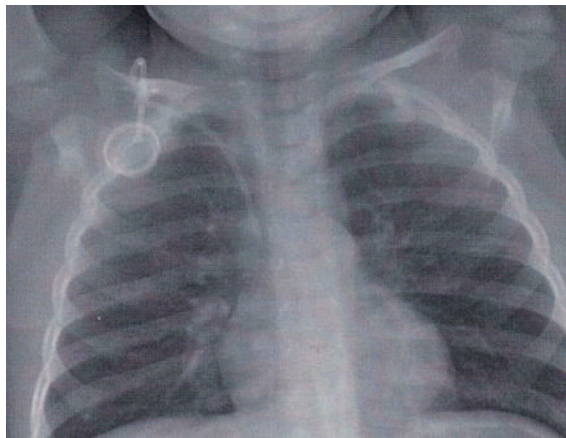


Figure 1: Chest X-ray immediately after implantation of the Port-a-Cath system showing the correct position of the system with the distal end of the canula in the superior vena cava.

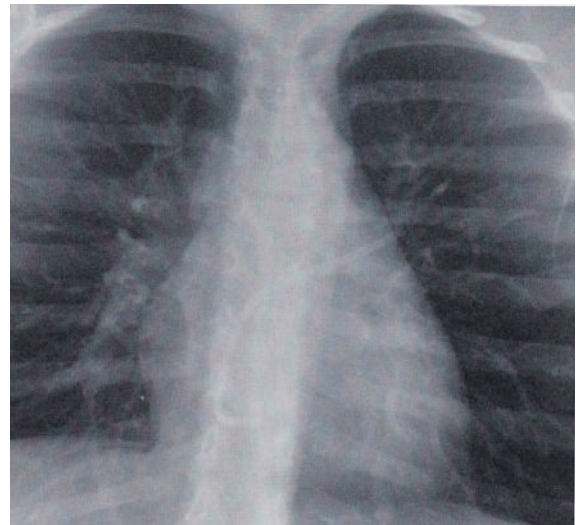


Figure 2: Chest X-ray 3 years after implantation of the Port-a-Cath prior to planned surgical removal of the system: the canula is disconnected from the box and straddles the PFO with the proximal end in the right atrium and the distal end in the upper left pulmonary vein, the catheter tip is seen just protruding outside the radiological heart shadow.

After the end of treatment and uneventful follow-up it was decided to remove the Port-a-Cath system surgically. A chest X-ray was performed prior to the intervention (fig. 2), which showed that, in the meantime, asymptomatic disconnection of the canula from the box of the system had occurred.

The catheter embolised into the heart, with one end of the canula being in the right atrium just above the tricuspid valve while the other end passed a patent foramen ovale (PFO) and remained stuck in the ostium of the upper left pulmonary vein, as also verified by echocardiography.

In the catheterisation laboratory, transvenous removal of the catheter was easy and uneventful; it was caught with an Amplatz Goose Neck snare from the proximal end in the right atrium and brought out through a 8F Mullins long sheath. No resistance was felt when it was removed from the left pulmonary vein and through the PFO.

Had the canula completely crossed the PFO and embolised into a sensitive vascular bed like that of the brain the incident could have found a fatal end.

Disclosure statement

No financial support and no other potential conflict of interest relevant to this article was reported.

Correspondence:
Prof. Dr. J.-P. Pfammatter
Center for congenital
heart disease
Freiburgstrasse
University Children's
Hospital
CH-3010 Bern
Jean-pierre.pfammatter[at]
insel.ch