

A sign of coronary artery disease?

Franck's sign

Florian Rey, Ulysse Voirol, Georgios Giannakopoulos

Division of Cardiology, Geneva University Hospitals, Geneva, Switzerland



Case description

A 61-year-old obese female with Parkinson's disease reported recurrent chest pain and exertional dyspnoea in the previous 24 hours. Clinical examination was

normal, but careful inspection of both ear lobes showed bilateral oblique creases extending backwards from the intertragic notch to the edge of the lobule (fig. 1, panels A–B). The electrocardiogram was unremarkable; however, cardiac troponin was mildly

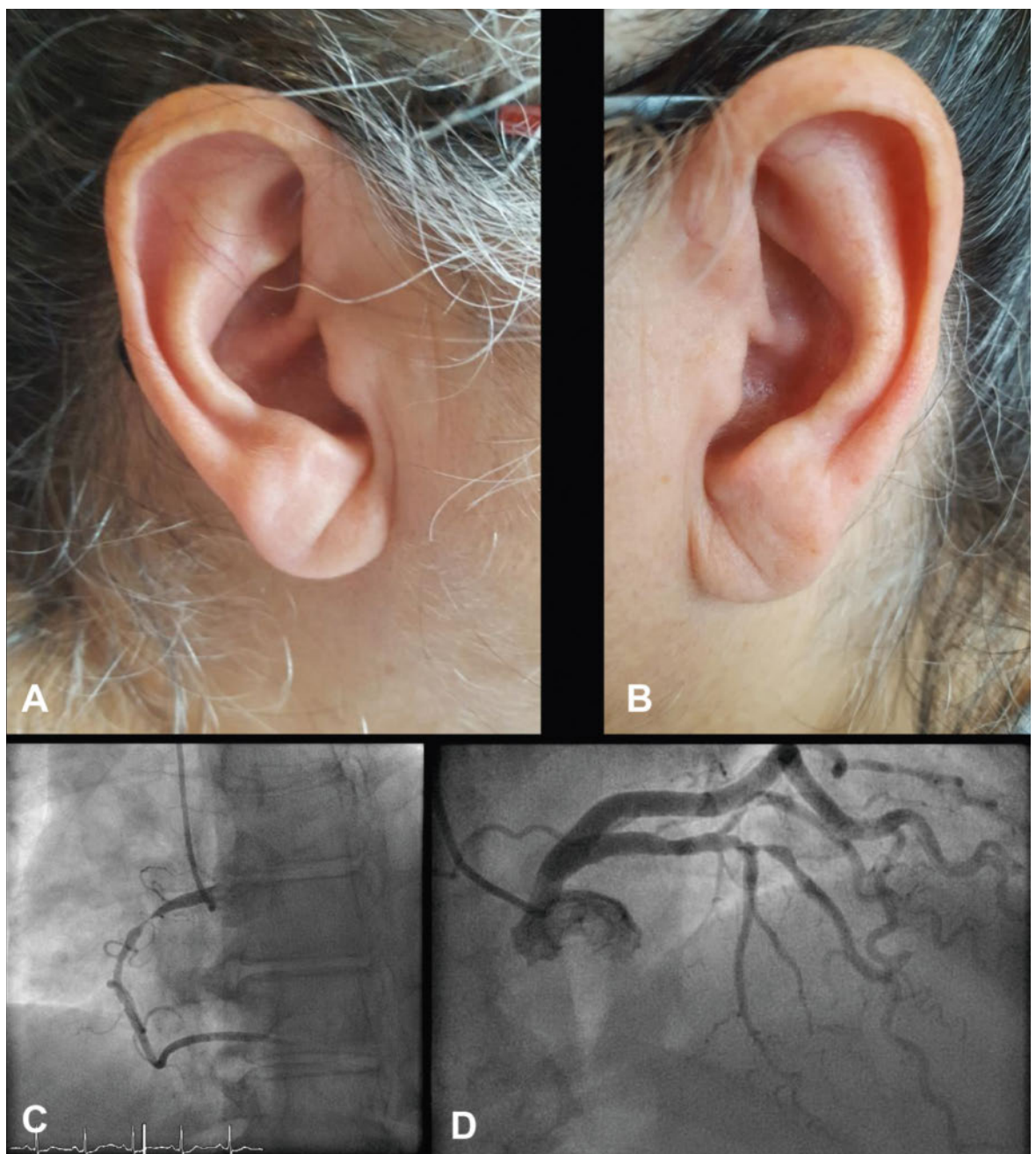


Figure 1: Panel A–B: Right and left ears with Franck's sign or ear lobe crease. Panel C: Proximal right coronary artery subocclusion. Panel D: Mid left anterior descending artery subocclusion. The patient gave her consent for the publication of the images.

elevated. A coronary angiogram showed two-vessel coronary artery disease, which was successfully treated with drug-eluting stents (fig. 1, panel C–D). The subsequent course was uneventful and the patient was discharged on dual antiplatelet therapy and a statin and counselled for intensive cardiovascular risk factor management including cardiac rehabilitation. Ear lobe crease, commonly referred as “Franck’s sign”, was initially described more than forty years ago by Sanders T. Franck, as a cutaneous sign of coronary artery disease. Several pathophysiological explanations have been proposed, including loss of elastic fibres due to increased free radical oxidative stress and diminished blood supply in the absence of collateral vessels in the ear lobe. A substantial number of studies

have evaluated the diagnostic performance of ear lobe crease as a marker of coronary artery disease. In a recent meta-analysis including more than 31 000 patients, Franck’s sign was associated with a 3.3-fold increase in the risk of coronary artery disease. The sign itself had sensitivity of 62% and specificity of 67%. The finding of Franck’s sign should thus prompt further questioning for conventional cardiovascular risk factors and family history of coronary artery disease.

Disclosure statement

No financial support and no other potential conflict of interest relevant to this article was reported.

Author contributions

Conception and design: FR, UV, GG. Drafting the manuscript for important intellectual content: FR, UV, GG.

Correspondence:
Ulysse Voirol
University of Geneva,
Medical Faculty
Rue Michel-Servet 1
CH-1206 Genève
ulyse.voirol[at]etu.unige.ch