

A very important diagnostic tool in patients with acute dyspnoea

Value of echocardiography in differentiation of acute dyspnoea

Ioannis Kapos, Felix C. Tanner

University Heart Centre Zurich, Department of Cardiology, Zurich, Switzerland

Summary

Echocardiography is one of the most effective imaging modalities for investigation of patients with acute dyspnoea. This review summarises appropriateness criteria and current guidelines for the use of cardiac ultrasound in common clinical scenarios presenting with acute dyspnoea, and illustrates such scenarios with typical echocardiographic findings.

Key words: acute dyspnoea; echocardiography; recommendations



Introduction

Dyspnoea is a common symptom defined as breathing discomfort or effort to breathe [1]. It leads numerous patients to the emergency department and is considered acute when developing over hours to days. There are several proposed methods for quantifying the degree of dyspnoea, such as the Modified Medical Research Council (mMRC) dyspnoea scale and the Borg scale [2, 3]. Although there is a broad differential diagnosis for acute dyspnoea, this can usually be narrowed down quickly by medical history and clinical examination, as well as additional diagnostic testing such as pulse oximetry, blood test (brain-type natriuretic peptide [BNP], blood count), electrocardiogram, chest radiograph, and, last but not least, echocardiography. The latter is one of the most powerful and versatile diagnostic tools available in the acute setting [4], and is particularly important since prompt diagnosis and proper therapy can improve outcome.

Pathophysiology

Dyspnoea is a result of the inability of the respiratory and/or circulatory system to maintain a balanced gas exchange and acid-base status. The complex pathophysiology behind this symptom is related to stimulation of various mechanoreceptors and chemoreceptors involving the peripheral and central nervous system. Depending on the organ primarily involved, the patients can be categorised into two groups, namely those with a respiratory and those with a

cardiovascular problem. Nevertheless, dyspnoea is caused by a combination of different mechanisms in most patients [5].

Respiratory

The respiratory system consists of a controller (brainstem), a ventilatory pump (peripheral nerves, chest wall, respiratory muscles and airways) and a gas exchanger (capillaries, alveoli and cell membrane). Dysfunction of any of these structures can cause an imbalance of circulating oxygen and carbon dioxide, which affects the rate and depth of breathing and is sensed as dyspnoea.

Cardiovascular

The function of the heart as a pump and haemoglobin as an oxygen transporter ensure sufficient tissue oxygenation. Thus, any cause of heart failure or anaemia can evoke an imbalance of ventilation and perfusion, which will be sensed as dyspnoea.

Differential diagnosis of acute dyspnoea

Possible diagnoses are listed in table 1.

Clinical assessment

History

An adequate medical history is very important for narrowing down the differential diagnosis. This is not always a simple task as patients may be unable to cooperate because of physical suffering, mental status or mechanical ventilation. In such occasions, history should be supplemented with information from family members or primary care providers.

Physical examination

Initial physical examination helps the physician to recognise a patient with respiratory distress and contributes to the differential diagnosis. The examination should include inspection of skin, mouth, throat, accessory respiratory muscles and extremities, as well as a cardiovascular and neurological exploration. The diagnostic value of pulmonary auscultation may be in-

Table 1: Differential diagnosis of acute dyspnoea.

Cardiac	Noncardiac
Heart failure <ul style="list-style-type: none"> – Acute on chronic vs acute – Systolic vs diastolic 	Upper airway causes <ul style="list-style-type: none"> – Obstruction (foreign objects) – Angio-oedema – Anaphylaxis – Infection – Airway trauma
Cardiomyopathies <ul style="list-style-type: none"> – DMC – HCM – RCM – ARVC – Non-compaction – Takotsubo 	Pulmonary causes <ul style="list-style-type: none"> – Pulmonary embolism – Exacerbation of COPD or asthma – Pulmonary infection – Pneumothorax – Lung cancer – ARDS
Acute coronary syndrome	Neurological causes <ul style="list-style-type: none"> – Stroke – Neuromuscular diseases
Valvular heart disease <ul style="list-style-type: none"> – Native valves (stenosis, regurgitation) – Prosthetic valves (obstruction, regurgitation) 	Mechanical causes <ul style="list-style-type: none"> – Pleural effusion – Ascites – Pregnancy – Obesity
Arrhythmias <ul style="list-style-type: none"> – Tamponade – Constriction – Effusive constrictive pericarditis 	Toxic and metabolic causes

ARDS = adult respiratory distress syndrome; ARVC = arrhythmogenic right ventricular cardiomyopathy; COPD = chronic obstructive pulmonary disease; DMC = dilated cardiomyopathy; HCM = hypertrophic cardiomyopathy; RCM = restrictive cardiomyopathy

ferior to that of medical history, particularly in the emergency room setting [6].

Supplementary examination

Further evaluation consists of chest X-ray, electrocardiography and laboratory testing for biomarkers such as the natriuretic peptides. If the plasma levels of natriuretic peptides are in the normal range, dyspnoea caused by heart failure is improbable. Nevertheless, disproportionately low levels may be seen in obese patients, end-stage heart failure, right heart failure or flash pulmonary oedema [7]. In addition, in cases of cardiac tamponade or pericardial constriction, the levels of natriuretic peptides may be normal [8, 9].

Cardiac ultrasound

Echocardiography has become one of the most effective tools for investigation of patients with acute dyspnoea. It is fast, versatile, noninvasive, can be performed in any clinical setting and provides extensive information on cardiac morphology and function, as well as on the central blood vessels leading to and from the heart. Hence, it provides essential information with implications for diagnostic accuracy, risk assessment and proper management of patients with acute dyspnoea. In the acute

setting, echocardiography can be performed as a complete comprehensive examination or as a problem-oriented approach also named focused cardiac ultrasound.

Comprehensive echocardiographic examination

A recently published consensus statement of the Working Group for Echocardiography and Cardiac Imaging of the Swiss Society of Cardiology underlines that the transthoracic echocardiographic examination performed by a cardiologist is not only expected to be of high quality and high accuracy, but also to represent a complete morphological and functional assessment of the heart, and to ensure standardised image acquisition, analysis and reporting [10]. It may be difficult to meet these requirements in the setting of a patient with acute dyspnoea. Suboptimal position of the patient, mechanical ventilation, thoracic trauma, central lines and drains are some of the causes of restricted echocardiographic windows, and nonstandardised echocardiographic views may be needed under such circumstances. Nevertheless, echocardiography performed by a cardiologist should be as comprehensive as possible, even under such conditions, in order to avoid overlooking important findings. In clinical practice, and in the setting of an acute decompensation in particular, very many patients suffer from several cardiac problems, and it can be detrimental for diagnosis and management to focus on a single aspect in a complex patient.

Focused cardiac ultrasound

Problem-oriented focused cardiac ultrasound has become a popular tool for physicians practicing in intensive care or emergency medicine. The only role of focused cardiac ultrasound is the rapid assessment of a symptomatic or unstable patient, to detect or exclude a major cardiac pathology such as large pericardial effusion, left ventricular global systolic dysfunction, right ventricular enlargement, or intravascular volume assessment [4]. It has been recognised that it can be reasonable for the rapid diagnostic evaluation of a patient with acute dyspnoea when medical professionals other than cardiologists perform a focused cardiac ultrasound in order to narrow down a differential diagnosis or to identify a main pathology. These colleagues should be sufficiently trained and should take care to maintain their level of skill, and both training and maintenance of skill should ideally be supervised by cardiologists [11, 12]. If the focused cardiac ultrasound reveals a pathology or if the findings of the focused ultrasound are not consistent with clinical presentation, a comprehensive echocardiographic examination should always be performed.

Appropriate use criteria

In an effort to define a reasonable application of cardiac ultrasound, the American College of Cardiology Foundation (ACCF) and the American Society of Echocardiography (ASE) reviewed various clinical scenarios and assessed various indications for echocardiography as appropriate, uncertain or inappropriate, according to the available evidence-based information and expert clinical experience. Appropriate cardiac ultrasound is expected to improve clinical outcome in a cost-effective manner; inappropriate use may likely be harmful for patients and/or cause extra cost (table 2) [13]. Although appropriate use criteria provide reasonable indications for application of echocardiography, the essential role of clinical judgment and experience in the management of individual patients should be stressed. Furthermore, it is important to emphasise that most of the appropriate indications for echocardiography in patients with acute dyspnoea require a comprehensive echocardiographic examination and cannot be accomplished adequately by a focused cardiac ultrasound [14].

Table 2: Recommendations for echocardiography in patients with acute dyspnoea.

Recommended:

- **Immediately** in haemodynamically unstable patients when acute heart failure is suspected
- **Immediately** in patients with shock or hypotension when pulmonary embolism is suspected and CT is not immediately available or contraindicated
- Within 48 h when cardiac function and structure are unknown or may have changed
- For differentiating cardiac from noncardiac aetiology of dyspnoea in patients in whom history/clinical/laboratory clues are inconclusive
- Intermediate risk patients (PESI III-IV) with suspected pulmonary embolism for further risk stratification implying different management
- Evaluation of a patient without chest pain but with other features of an ischaemic equivalent or laboratory markers indicative of ongoing myocardial infarction

Not recommended:

- When noncardiac aetiology is obvious and the expected additional information does not affect management
- As elective diagnostic strategy in haemodynamically stable and normotensive patients with suspected pulmonary embolism

Clinical scenarios presenting with acute dyspnoea: cardiac causes

Heart failure

Echocardiography should be performed early since the signs and symptoms of heart failure are neither very sensitive nor specific and since there is a broad spectrum of possible underlying causes in patients presenting with acute dyspnoea and suspected heart failure. According to the current European Society of Cardiology (ESC) guidelines for heart failure, echocardiography is recommended immediately in haemodynamically unstable patients or, alternatively, within 48 hours when cardiac function and structure are either not known or

may have changed [7]. Echocardiography does not only provide detailed information on chamber volumes, ventricular function, valvular function, pericardial effusion, pulmonary pressure, and much more, but is also essential for distinguishing heart failure caused by systolic from diastolic dysfunction [7].

Evaluation of systolic function

Depending on left ventricular ejection fraction (LVEF), patients with heart failure can be categorised into those with preserved (EF >50%, HFpEF) and those with reduced LVEF (EF <40%, HFrEF). The current ESC guidelines for heart failure introduced a new category for patients with so-called mid-range LVEF (EF 40–49%); however, this group of patients has been investigated less thoroughly than the other two groups.

The recommended method for assessing LVEF at present is the disc summation method with use of two orthogonal apical views (modified Simpson's method). Three-dimensional echocardiography may be applied if image quality is adequate; however, normal values for 3D left ventricular volumes are less well documented than 2D values and differ from the latter. Left ventricular deformation analysis, in particular global longitudinal strain, may offer incremental functional and prognostic information over that provided by LVEF and is at this time recommended for special patient groups such as those who have undergone chemotherapy [7, 15].

Probably more important for clinical practice than advanced applications, is to remember a few basic considerations on echocardiographic measurement of LVEF. Translational motion of the heart hampers the accurate interpretation of ventricular borders and wall motion and needs to be avoided, which can be difficult in patients with acute dyspnoea. Foreshortened apical views are a common problem particularly in the emergency setting; hence, the length of the left ventricle needs to be compared between four-chamber and two-chamber views, and differences above 10% should not be accepted. Finally, LVEF should be distinguished from stroke volume; although both are closely related to cardiac function, they may be discordant, such as in patients with mitral regurgitation.

Evaluation of diastolic function

Impaired myocardial relaxation, reduced restoring forces, and increased cardiac stiffness are the three main mechanical factors leading to left ventricular diastolic dysfunction and increased filling pressure. Filling pressure can be assessed with various methods that determine different aspects of diastole such as pulmonary capillary wedge pressure (PCWP), left atrial pressure (LAP), and left ventricular end-diastolic pressure

(LVEDP) [16]. Left ventricular diastolic pressure can be estimated by means of Doppler echocardiography [17]. There is a broad list of 2D and Doppler-derived parameters available for assessment of left ventricular diastolic function, with each method having its advantages and limitations, which are primarily related to the fact that most echocardiographic parameters estimate diastolic pressure either in early or late diastole.

The most frequently used parameters include transmitral E velocity and E/A ratio, mitral annulus early diastolic velocity (e') and E/ e' ratio, left atrial volume index, and tricuspid regurgitation peak systolic flow velocity. These parameters exhibit wide reference ranges and depend on age as well as other conditions, such as underlying pathology, haemodynamic factors and Doppler signal quality. Therefore, it is not wise to estimate diastolic function from a single parameter only. In a practical approach, the updated guidelines for echocardiographic evaluation of left ventricular diastolic function propose a new algorithm that aims to simplify the application of several parameters for the evaluation of diastolic function. By use of this algorithm and, if required, additional parameters for diastolic function, the echocardiographer should be able to distinguish normal from abnormal diastolic function and estimate filling pressure as well as grade of diastolic dysfunction.

There is evidence that echocardiographic estimation of filling pressure can be used to guide more efficient treatment and results in reduced morbidity from heart failure [18]. Advanced echocardiographic methods such as left ventricular deformation analysis seem to be particularly valuable for distinguishing dyspnoea due to HFpEF from dyspnoea for other reasons, and global

longitudinal strain predicts all-cause mortality in both HFpEF and HFpEF patients [19, 20]. Finally, strain analysis of the left atrium holds promise for evaluation of atrial dysfunction and estimation of left ventricular filling pressure [21].

Again, apart from these promising developments, it is good to remember a few basic considerations on the echocardiographic evaluation of diastolic function. Transducer position, sample volume, velocity scale and signal quality should be adequate. The effect of respiration on sample volume position and on blood flow velocity should be considered particularly in patients with dyspnoea. A normal left atrial size is rarely associated with a significant diastolic dysfunction, which can be helpful when Doppler-derived parameters provide discrepant values.

Lung ultrasound

Lung ultrasound may prove to be a valuable tool for examination of pulmonary congestion in both systolic and diastolic heart failure. Increased extravascular lung water alters the normal ultrasound signal generated by the lung through reverberation artefacts known as sonographic B-lines. The number of these correlates with the volume of extravascular lung water, with <5 B-lines considered as normal and >30 B-lines suggestive of pulmonary oedema. Standard protocols for quantification of B-lines have been proposed and are being evaluated for their usefulness in clinical routine [22].

Cardiomyopathies

Any cardiomyopathy may elicit acute dyspnoea as a symptom of acute heart failure or an acute exacerbation of chronic heart failure. Echocardiography is validated as the most appropriate imaging modality for defining the reason for acute heart failure in both the initial evaluation of a suspected cardiomyopathy and the acute deterioration of a known cardiomyopathy [12, 13].

LVEF is certainly important for the assessment of systolic function in patients with cardiomyopathies. Additional diagnostic and prognostic value is offered by the use of strain analysis. In the early stages of hypertrophic cardiomyopathy, global longitudinal systolic strain is reduced, although radial and circumferential strain may be well preserved, maintaining LVEF within a normal range. This pattern may also point towards a higher degree diastolic dysfunction [23]. In addition, infiltrative cardiomyopathies such as cardiac amyloidosis often present with a typical pattern of preserved longitudinal systolic strain in the apical, but not the basal, left ventricular segments, resulting in a so-called apical sparing pattern and providing potentially useful incremental diagnostic information (fig. 1).

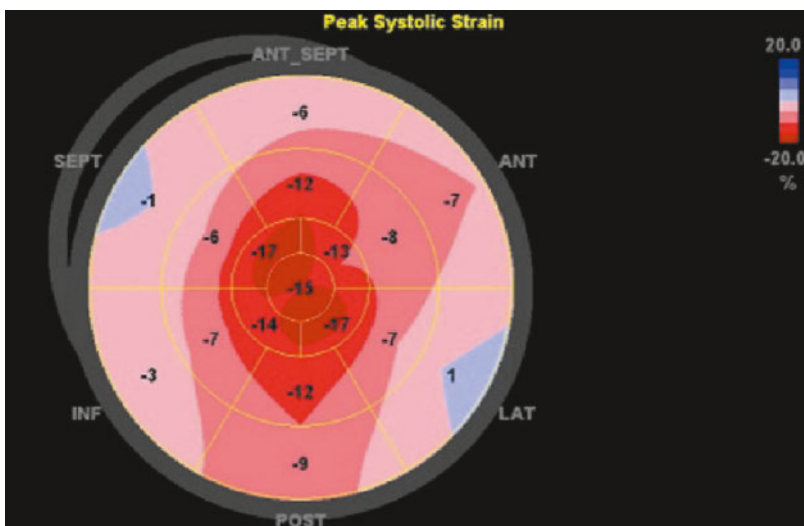


Figure 1: Cardiac amyloidosis. Global longitudinal strain is -9.4% and thus severely reduced; there is an apical sparing pattern of longitudinal strain.

Echocardiography is not only essential for diagnosis and risk assessment of patients with acute dyspnoea due to a cardiomyopathy, but may also be valuable for proper haemodynamic management. In the event of hypovolaemia or with application of positive inotropic agents, left ventricular dynamic obstruction may be exacerbated in patients with hypertrophic cardiomyopathy. Doppler echocardiography can accurately identify the level of obstruction, the presence of a significant mitral regurgitation caused by systolic anterior motion of mitral leaflets and the effect of adaptations in therapeutic management.

Acute coronary syndrome

Whereas most patients with acute coronary syndrome exhibit chest pain, one third may sense no pain and instead present with other symptoms such as acute dyspnoea. These patients are at a high risk for delays in diagnosis and appropriate therapy [24]. Consistent with this, chest pain is not necessarily required for establishing the diagnosis, according to the universal definition of myocardial infarction. Immediate echocardiography may help to identify patients with acute myocardial ischaemia, in particular when the initial diagnostic tools such as electrocardiogram and cardiac biomarkers are inconclusive. In such cases, echocardiography may discover and localise new wall-motion abnormalities indicative of myocardial injury [12]. Analysis of myocardial strain may provide incremental diagnostic value over conventional echocardiography in this context [25]. According to the current ESC guidelines for patients with non-ST elevation myocardial infarction (NSTEMI), echocardiography is recommended for evaluating global and regional left ventricular function, as well as for assessing differential diagnoses; it should be performed urgently in all patients with haemodynamic instability [26]. Echocardiography is also very useful for investigating complications of myocardial infarction when an acute coronary syndrome is suspected (fig. 2).

Valvular heart disease

Both patients with a new heart murmur and those with known valvular heart disease may present with acute dyspnoea. Echocardiography is the key examination in such a situation. Echocardiography allows valvular morphology and function to be determined; thereby, it provides information on the origin as well as the severity of disease. Moreover, it assesses changes in cardiac chamber dimensions and ventricular function, providing important clues on the course of disease as well as on the impact of valvular disease on cardiac performance. For instance, a severe valvular regurgitation is consistent with normal dimensions of cardiac cham-

bers if it occurs in an acute setting, but not in the context of otherwise uncomplicated chronic valvular heart disease. Echocardiography can also identify complications of valvular heart disease such as thrombus formation and endocarditis [27, 28]. Finally, it generates information important for patient management such as criteria for the appropriateness of balloon valvuloplasty in patients with significant mitral stenosis. Hence, echocardiography clarifies whether an episode with acute dyspnoea is related to valvular heart disease, evaluates the consequences of valvular disease for cardiac function, identifies possible complications, provides evidence for treatment decisions, and eventually guides therapeutic interventions in the hybrid operating room (fig. 3).

There is a wide range of qualitative, semiquantitative, and quantitative echocardiographic parameters available for quantification of valvular dysfunction. In most situations, it is advisable to combine as many of these parameters as possible for accurate quantification of stenotic and, particularly, of regurgitant lesions. In pa-

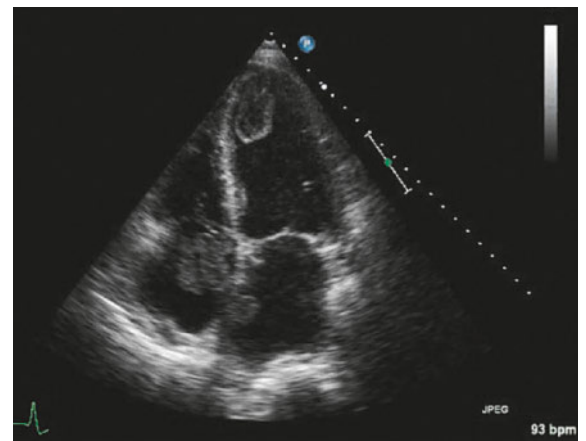


Figure 2: Acute myocardial infarction with severe acute heart failure. Apical four-chamber view shows a thrombus in each of the left ventricle, the left atrium and the right atrium. Thrombus in the three cardiac cavities was confirmed by autopsy.

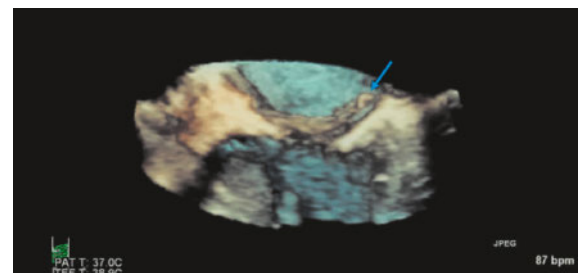


Figure 3: 3D-transoesophageal echocardiography with 3D-zoom on the mitral valve. Acute mitral regurgitation due to flail leaflet after an acute inferior myocardial infarction. There is a piece of papillary muscle attached to the chordae (arrow).

tients with acute dyspnoea, however, echocardiographic examination is often hampered by poor image quality, and under such conditions it may be wise to rely on morphological information and semiquantitative parameters such as vena contracta width, rather than more complex quantitative values like regurgitant volume or effective regurgitant orifice area. Doppler parameters derived from larger vessels, such as diastolic flow reversal in the abdominal aorta due to aortic regurgitation, or systolic flow reversal in a pulmonary vein due to mitral regurgitation, may provide very helpful supplementary information, including in the emergency ward. As the severity of valvular regurgitation may vary with the haemodynamic state of the patient, instantaneous blood pressure, heart rate, haemoglobin level and use of positive inotropic agents or positive pressure ventilation should be taken into consideration [27].

Prosthetic valve dysfunction

If acute dyspnoea occurs during the early post-procedural period in a patient with a prosthetic heart valve, surgical or interventional complications such as pleural effusion, pericardial tamponade, dissection of atria or vessels, and embolisation, dehiscence or dysfunction of the prosthesis should be excluded. The latter can be related to stenosis and/or regurgitation; in the acute setting, it is usually caused by thrombosis or endocarditis (fig. 4). The incidence of prosthetic valve complications depends on the prosthesis type and position, the adequacy of anticoagulation, and other clinical risk factors. Prosthetic valve obstruction should principally be suspected when an increase from baseline in transprosthetic pressure gradient is observed. However, in patients with acute dyspnoea, this needs to be differentiated from increased stroke volume due to high-output states or a concomitant acute regurgitation. The relative

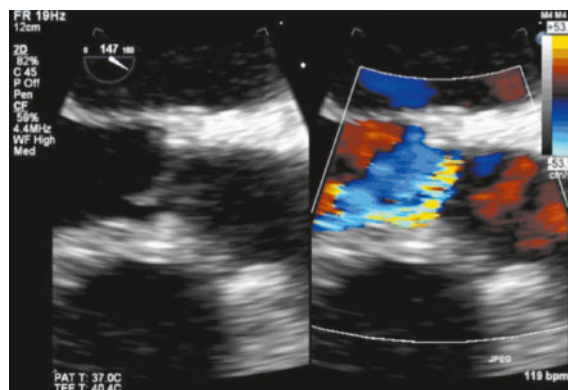


Figure 4: Transoesophageal echocardiography in the long axis view with zoom on an aortic bioprosthesis. Acute transvalvular regurgitation due to flail leaflet (right coronary position) after an endocarditis. There is severe eccentric regurgitation due to the flail.

changes of pressure gradient and pressure half-time may help with this distinction and, in particular, provide important indications of a new paravalvular leak, which might otherwise have been overlooked in such a dyspnoeic patient. Another potentially useful Doppler signal characteristic in patients with acute dyspnoea is acceleration time corrected for ejection time, which allows differentiation between prosthesis stenosis and patient-prosthesis mismatch, and may be useful when there is only little information on the patient available in the emergency setting [29, 30].

A transthoracic study may not reveal the reason for a prosthesis dysfunction, particularly in postoperative patients with insufficient acoustic windows or because of artefacts caused by the prosthesis. In such cases, transoesophageal echocardiography should be performed, given that the respiratory state of the patient has been stabilised or the patient been intubated [31].

Cardiac arrhythmia

Although dyspnoea is not the primary symptom of patients presenting with cardiac arrhythmias, the latter may lead to imbalance of myocardial oxygen demand and supply due to inadequate stroke volume and thus cause acute dyspnoea [32]. The role of echocardiography consists in excluding structural heart disease that elicits supraventricular or ventricular arrhythmias, such as ischaemic heart disease, valvular heart disease, cardiomyopathies, or systemic diseases involving the heart like sarcoidosis. Furthermore, echocardiography provides information on complications of cardiac arrhythmias such as thrombus formation or tachycardia-induced cardiomyopathy. The latter should be suspected in cases of newly diagnosed heart failure of unknown origin if patients present with sustained or paroxysmal cardiac arrhythmias (tachyarrhythmias or ventricular

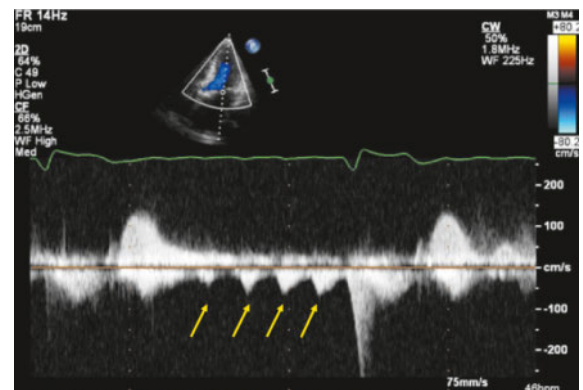


Figure 5: CW-Doppler spectrum showing repetitive short-lasting signals corresponding to diastolic mitral regurgitation in a patient with atrial flutter as well as third-degree atrioventricular block. There is also systolic mitral regurgitation.

ectopy) (fig. 5). As it is difficult to determine whether cardiac arrhythmia is the cause or the consequence of heart failure, the diagnosis should only be established when other structural causes have been excluded and the ejection fraction improves after adequate control of heart rate or rhythm. Although there is no established echocardiographic criterion differentiating arrhythmia-induced cardiomyopathy from other causes of dilated cardiomyopathy, left ventricular end-diastolic dimension was the only predictor of tachycardia-induced cardiomyopathy in one study [33].

Pericardial compressive syndromes

Pericardial compressive syndromes occur when there is accumulation of pericardial fluid (tamponade), a non-compliant thickened pericardium (pericardial constriction), or a combination of the two (effusive-constrictive pericarditis). Dyspnoea is considered one of the most common symptoms in this context and, depending on the aetiology, it can develop either gradually or acutely.

Cardiac tamponade

Depending on the time course of pericardial fluid accumulation, cardiac tamponade may represent an important reason for acute dyspnoea. Chest trauma, aortic dissection, complications of myocardial infarction, cardiac interventions or cardiac surgery may all lead to acute tamponade. Even though tamponade is essentially a clinical diagnosis, echocardiography plays a key role in assessing the amount of pericardial effusion and its haemodynamic significance (fig. 6).

In patients suffering from acute dyspnoea, it may be difficult to derive reliable information from the respiratory variation of mitral inflow induced by ventricular interdependence, because image plane and Doppler

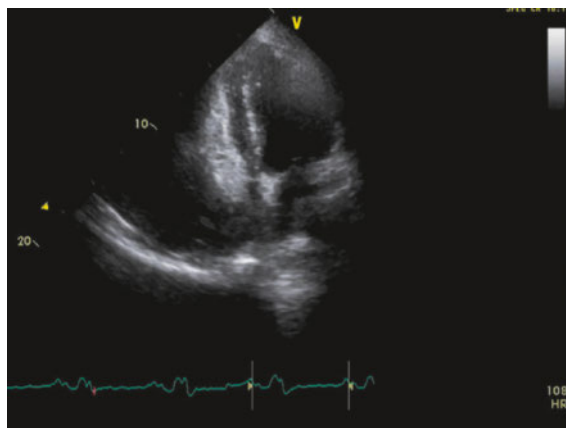


Figure 6: Apical four-chamber view in a patient with cardiac tamponade. There is pronounced compression of right atrium and right ventricle.

sample volume are subjected to excessive respiration-induced translational motion. Under such conditions, it is particularly advisable to rely primarily on signs of haemodynamic significance detectable on gray-scale image, such as diastolic collapse of the right atrium and right ventricle, respiratory variation in ventricular chamber size and ventricular septum motion, and dilatation of the inferior vena cava. A combination of clinical and echocardiographic parameters certainly is best for establishing the diagnosis of cardiac tamponade and defining the urgency of pericardiocentesis. In postoperative patients after heart surgery, cardiac tamponade should always be suspected in cases of haemodynamic instability. Even a small or localised pericardial effusion may cause a tamponade because of the acute onset of the effusion and the reduced compliance of the pericardium, and this may be easily overlooked in a transthoracic study, particularly if the effusion is localised inferiorly and the echo window is of insufficient quality. In such situations, intravenous application of ‘bubbles’ may be very helpful and is highly recommended. If the transthoracic study is still not conclusive, but the clinical suspicion is high, there should be no delay in performing transoesophageal echocardiography, and attention should be given to the acquisition of transgastric views in order to exclude a localised effusion [31].

Pericardial constriction and effusive-constrictive pericarditis

Constriction is caused by an inflamed, thickened or calcified pericardium impairing cardiac filling. The haemodynamic mechanism of reduced stroke volume is similar to that of cardiac tamponade, and mainly caused by ventricular interdependence. Constriction rarely accounts for acute dyspnoea, whereas the combination of constriction and effusion encountered in effusive-constrictive pericarditis is more often involved [16]. The latter should be suspected if a restrictive mitral inflow pattern coexists with a high or normal Doppler tissue velocity of the septal mitral annulus [34].

Clinical scenarios presenting with acute dyspnoea: noncardiac causes

Pulmonary embolism

Acute dyspnoea is a common symptom in acute pulmonary embolism, being present in more than 70% of patients [35]. As other diagnostic tests such as D-dimer, CT and V/Q scanning provide higher sensitivity and specificity, echocardiography is not considered a key diagnostic test for the diagnosis of pulmonary embolism, at

least in haemodynamically stable patients. Unless an embolus is visualised in the right-sided cardiac cavities or the pulmonary artery, echocardiographic findings are neither very sensitive nor specific; they may be missed in almost half of the cases with pulmonary embolism, and signs of right ventricular dysfunction may be present in patients with right ventricular myocardial infarction or pulmonary hypertension (fig. 7). Hence, transthoracic echocardiography should not be performed routinely in haemodynamically stable patients (not high-risk) when pulmonary embolism is suspected. On the other hand, echocardiography has an important value in haemodynamically unstable patients when CT-angiography is not immediately available or when only bedside tests are possible in critically ill patients. Furthermore, echocardiography is needed for risk assessment and for guiding management strategies in haemodynamically stable patients at intermediate risk.

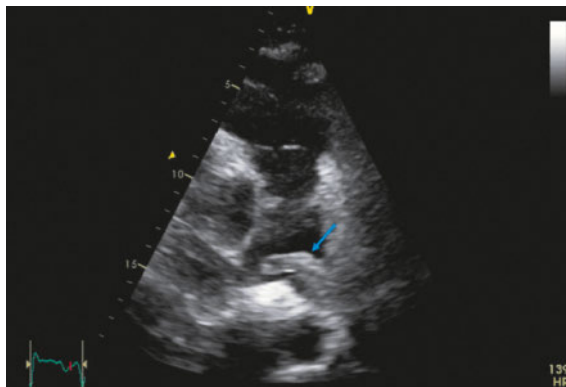


Figure 7: Modified parasternal short axis view with focus on the pulmonary artery. A large embolus (arrow) occluding the left pulmonary artery and protruding in right pulmonary artery is depicted in a patient with acute pulmonary embolism.

The main indirect echocardiographic findings in pulmonary embolism include dilatation of right-sided cardiac cavities and decreased systolic function of the right ventricle. An interesting additional parameter consists of regional wall motion abnormalities of the right ventricular free wall, known as McConnell's sign; patients with acute pulmonary embolism frequently display normal or hyperdynamic contraction of the right ventricular apex, while the remainder of its free wall is hypokinetic or akinetic (fig. 8). Systolic pulmonary artery pressure may also be estimated if tricuspid regurgitation is present. Rarely (<4%) specific echocardiographic findings can be made such as the presence of emboli in right-sided cardiac cavities [12, 36].

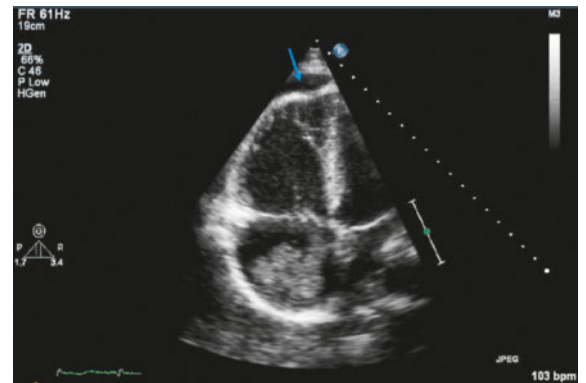


Figure 8: Modified apical four chamber view with focus on the right ventricle in a patient suffering from acute pulmonary embolism due to embolisation of right atrial myxoma. Dilated right ventricle with typical configuration due to hypercontractile apex and hypo/akinesia of the mid-wall region (McConnell's sign; arrow).

Stroke

Although dyspnoea is not the main complaint of patients with stroke, respiratory problems may occur depending on the localisation and severity of cerebral injury. Echocardiography should be performed in all patients with embolic stroke and, depending on the age of the patient, comorbidities, and pretest-probability, transthoracic echocardiography, either alone or complemented by transoesophageal echocardiography, should be performed to investigate a potential source of embolism. As undetermined (cryptogenic) strokes account for 30–40% of all ischaemic strokes, the presence of persistent foramen ovale, atrial septal defect or atrial septal aneurysm and eventually atrial septal pouch should be properly examined with the use of agitated saline with and without Valsalva manoeuvre [37].

Conclusion

Echocardiography has become a very important diagnostic tool in patients with acute dyspnoea. It is fast, noninvasive, cost-effective and readily repeatable, and offers great value for accurate diagnosis, differential diagnosis, risk stratification, therapeutic monitoring, and interventional guidance in such patients.

Disclosure statement

No financial support and no other potential conflict of interest relevant to this article was reported

References

The full list of references is included in the online version of the article at www.cardiovascmed.ch.

Correspondence:
Prof. Dr. med. Felix C. Tanner
Leitender Arzt Kardiologie
Leiter Echokardiographie
Universitäres Herzzentrum
Zürich
Rämistrasse 100
CH-8091 Zürich
[felix.tanner\[at\]usz.ch](mailto:felix.tanner[at]usz.ch)