

Modified surgical access

Preservation of a tattoo during subcutaneous ICD implantation with uncompromised device function

Devdas T. Inderbitzin^{a,b}, Ardan M. Saguner^b, Jan Steffel^c, Aaron Imhof^a, Alexander Breitenstein^b

^aDepartment of Cardiac Surgery, University Heart Centre Zurich, University Hospital Zurich, Switzerland; ^bDepartment of Cardiology, Electrophysiology and Cardiac Devices, University Heart Centre Zurich, University Hospital Zurich, Switzerland; ^cHerzKlinik, Klinik Hirslanden, Zurich, Switzerland

Summary

We report a modified surgical access for subcutaneous implantable cardioverter defibrillator implantation to preserve an artistic tattoo providing uncompromised device positioning and function in a 35-year-old patient with Brugada syndrome.

Case description

A 35-year-old male patient was referred from an outside hospital after surviving a sudden cardiac arrest. Subsequent cardiac assessment revealed Brugada syndrome and implantation of an implantable cardioverter defibrillator (ICD) for secondary prevention was planned. As there was no need for cardiac pacing in the near future, a subcutaneous ICD (S-ICD) was chosen. Pre-interventional diagnostics demonstrated that all three vectors for the S-ICD fulfilled the screening criteria. However, at the site of the device pocket the patient had an artistic cutaneous tattoo showing a clock with Roman numbers. Surgery was performed with an interdisciplinary approach by a cardiologist and cardiac surgeon with the particular intention to preserve the tattoo. In order to minimise the risk for optical distortion of the clock, the device pocket access was anteriorised and the cutaneous incision was made at the anterior margin of the tattooed clock by a semi-circular incision on the level of the anterior axillary line. Despite this unusual anterior access, subcutaneous blunt preparation of the inter-muscular device pocket between the latissimus dorsi and anterior serratus muscle was uneventful (fig. 1A). Hence, the device could be placed in the correct position providing an optimal vector for defibrillation with the parasternal subcuta-

neous lead. After fixation of the device to the serratus anterior fascia, the pocket was closed layer by layer and an intra-cutaneous suture using Maxon 4/0 along the anterior margin of the clock was performed to close the wound (fig. 1B). Post-implant device testing revealed an uncompromised device function and radiographic imaging confirmed a correct position of the ICD (fig 1D, E).

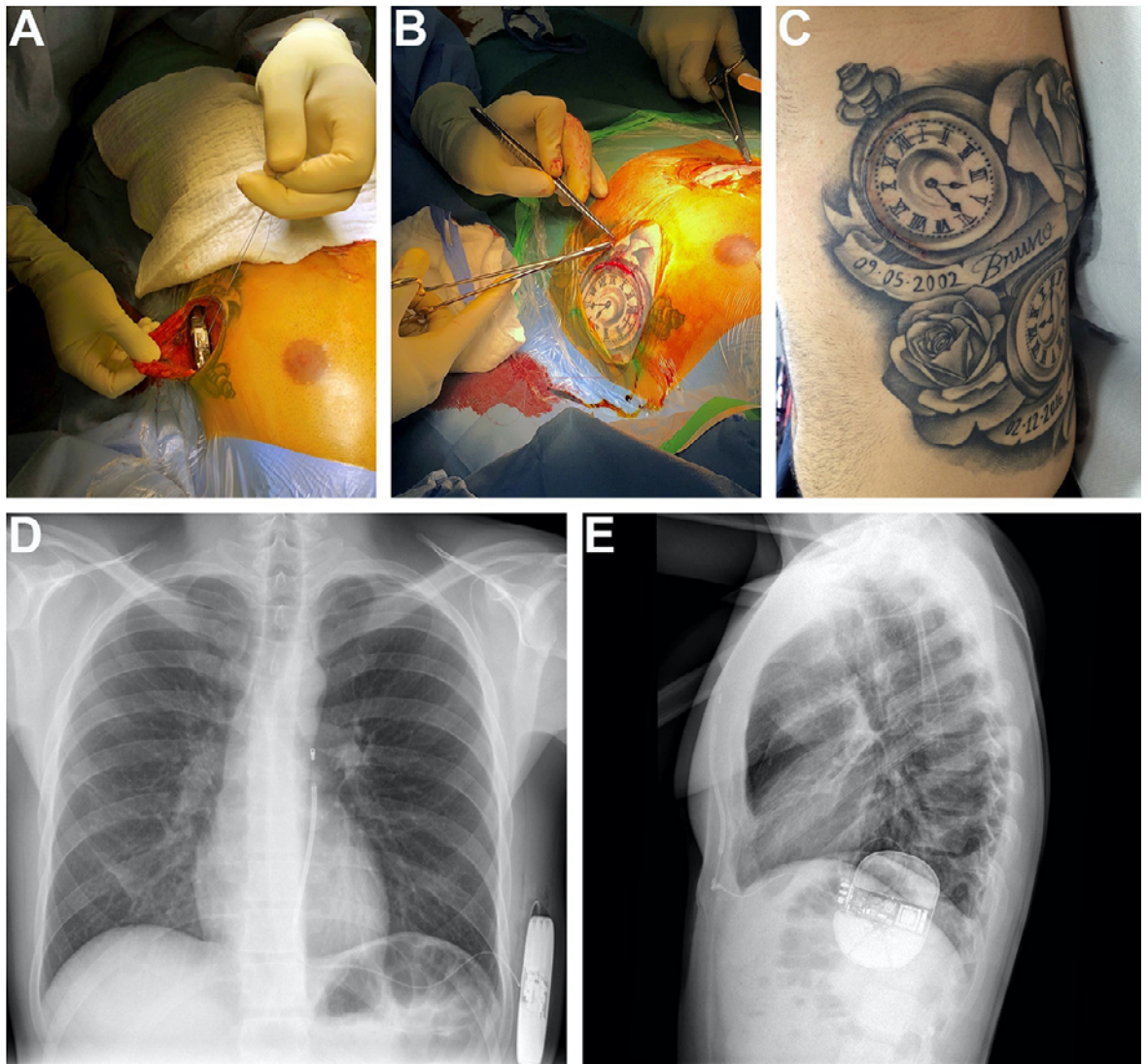
During post-interventional follow-up 4 weeks after surgery the patient had no arrhythmic events or ICD shocks and an uncomplicated wound healing with an aesthetic cicatrisation without optical distortion of the filigree tattoo (fig. 1C).

Conclusion

This case demonstrates successful optical preservation of an artistic tattoo by a modified surgical access for S-ICD implantation without restriction of neither an optimal device position nor its function.

Disclosure statement

Dr. Steffel has received consultant and / or speaker fees from Abbott, Alexion, Amgen, Astra-Zeneca, Bayer, Berlin-Chemie, Biosense Webster, Biotronik, Boehringer-Ingelheim, Boston Scientific, BMS, Daiichi Sankyo, Medscape, Medtronic, Merck/MSD, Organon, Pfizer, Saja, Servier, and WebMD. He reports ownership of CorXL. Dr. Steffel has received grant support through his former institution (University Hospital Zurich) from Abbott, Bayer Healthcare, Biosense Webster, Biotronik, Boston Scientific, Daiichi Sankyo, and Medtronic. Dr. Breitenstein has received consultant and / or speaker fees from Abbott, Bayer Health Care, Biotronik, BMS/Pfizer, Boston Scientific, Daiichi Sankyo, and Medtronic. Dr. Breitenstein has received educational grant from Biosense Webster, Biotronik and Actelion. Dr. Breitenstein has received speaker honoraria from Abbott, Biotronik, BMS/Pfizer, Bayer Health Care, Abbott, Spectranetics/Philipps, and Medtronic. Dr. Saguner has received a speaker honorarium from Boston Scientific and educational grants from Abbott, Biotronik, BMS/Pfizer and Boston Scientific.



Devdas Thomas Inderbitzin,
MD
Department of Cardiac
Surgery
University Hospital Zurich
Raemistrasse 100
CH-8091 Zurich
Devdasinderbitzin[at]
bluewin.ch

Figure 1 (A) Intermuscular device pocket with device box through modified anteriorized access along the anterior margin of the tattooed clock. (B) Wound closure by using resorbable intracutaneous suture. (C) Postoperative result of cicatrisation at 4 weeks after surgery without distortion of the tattooed clock and without distraction of its optical geometry. (D, E) Thoracic radiography (anterior-posterior as well as lateral view) demonstrating normal device and lead position.